

# Anatomic factors predict urinary continence in patients with anorectal malformation

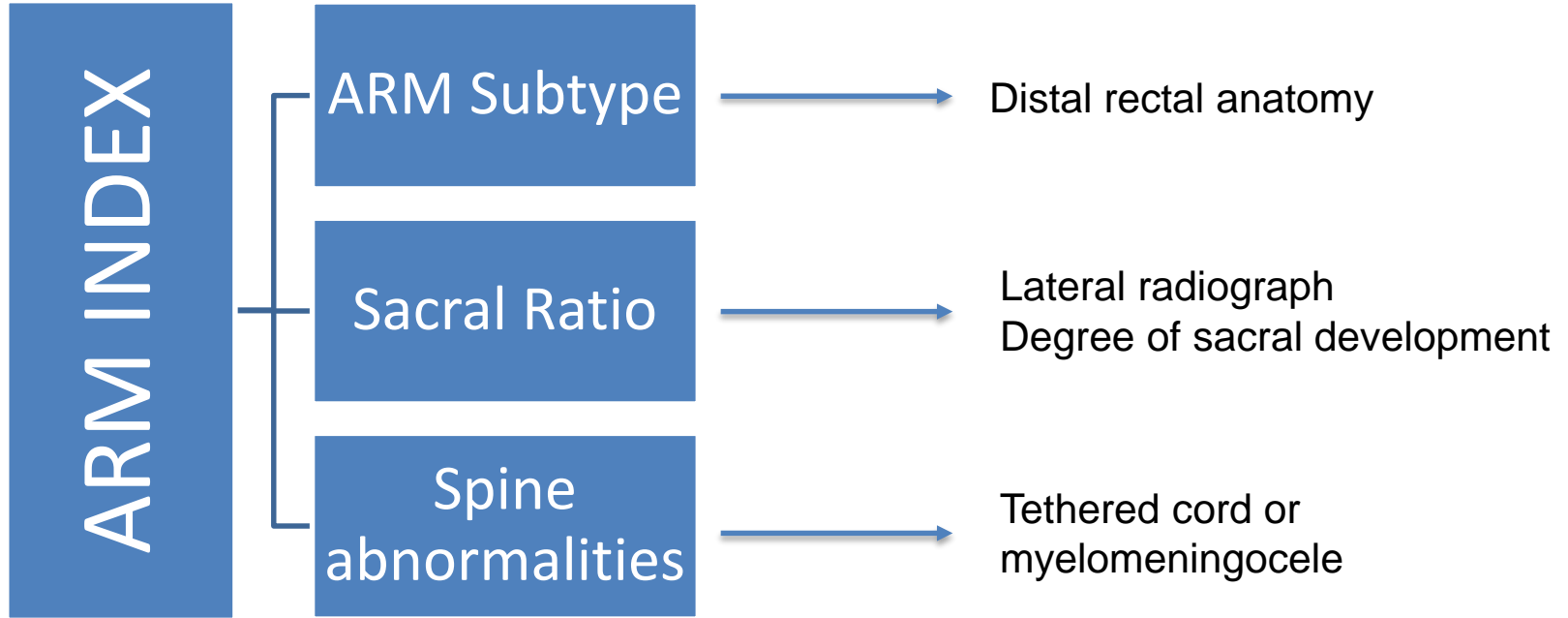


Molly E Fuchs, Devin R Halleran, Yuri Sebastião, Laura Weaver, Hira Ahmad,  
Christina B Ching, Marc A Levitt, Richard J Wood and Daniel G Dajusta

# Background

- Anorectal malformation a complex spectrum diagnosis characterized by anal mislocation
- Associated with spinal cord and sacral anomalies

# Background



# Background

- ARM index has been shown to predict fecal continence
- No tool exists to predict urinary continence

# Purpose

- To identify if the anatomic factors that make up the ARM index are associated with urinary continence in ARM

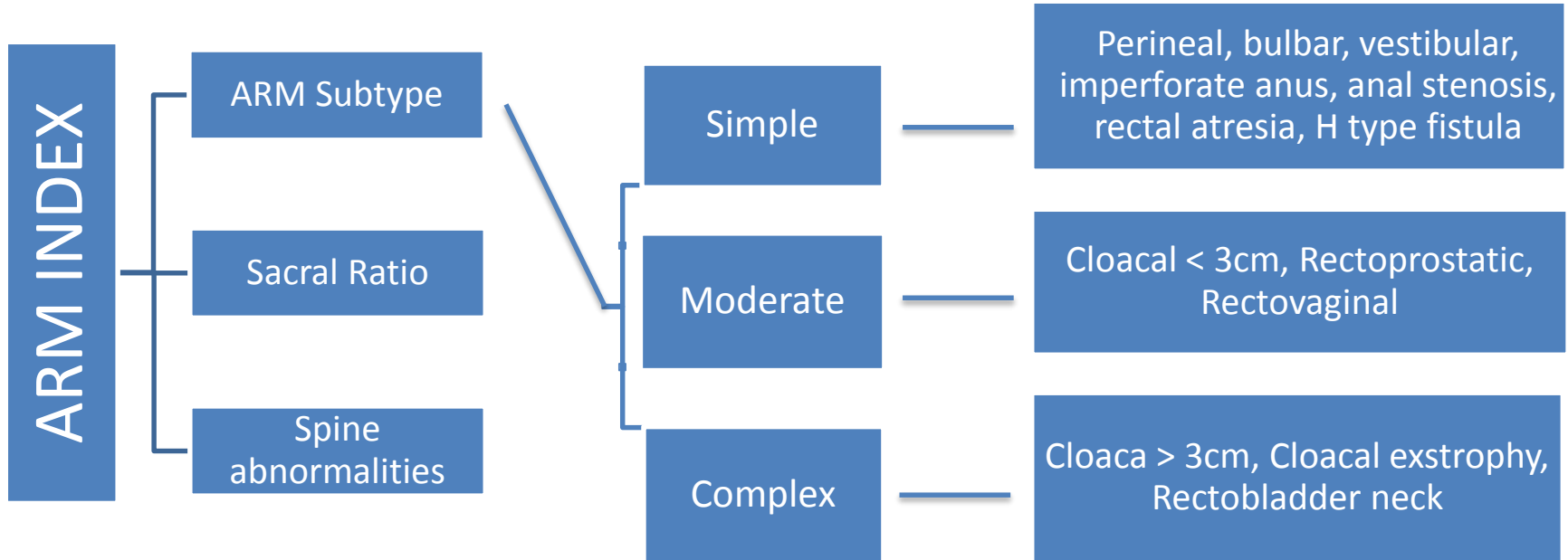
# Methods

- Review of large ARM database
- Inclusion criteria
  - Age > 4 yrs
  - Complete data
  - Patient reported continence

# Methods

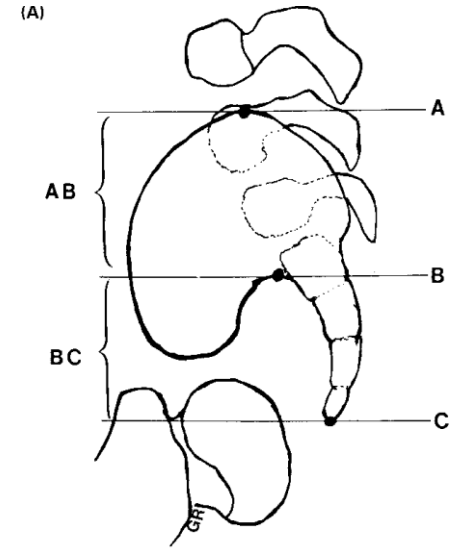
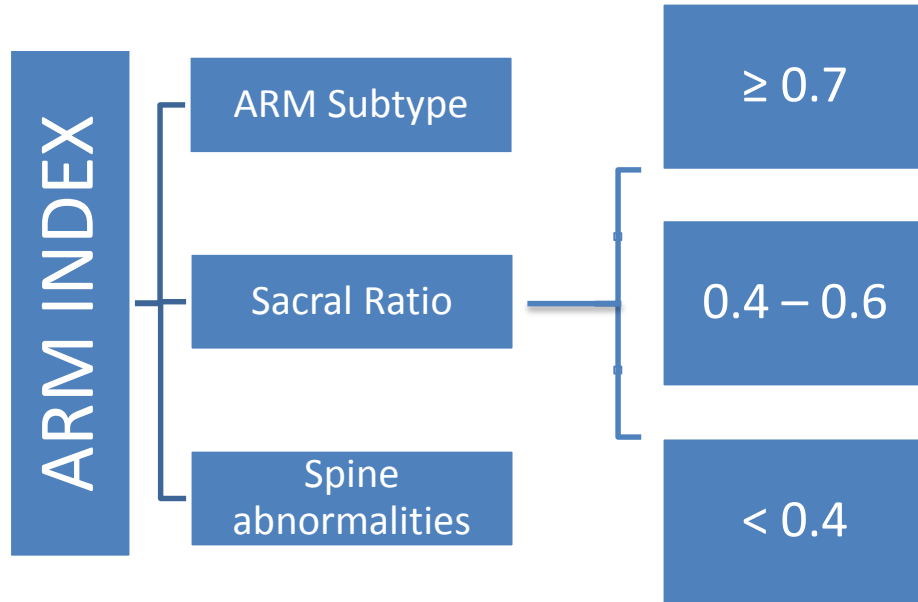
- Definition of continence
  - Volitional voiding per urethra
  - Dry between daytime voids
  - $\leq 1$  accident per week

# Methods

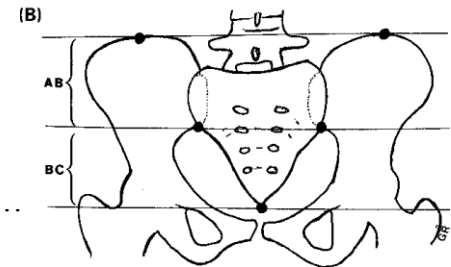




# Methods



Normal Ratio:  $\frac{BC}{AB} = .77$

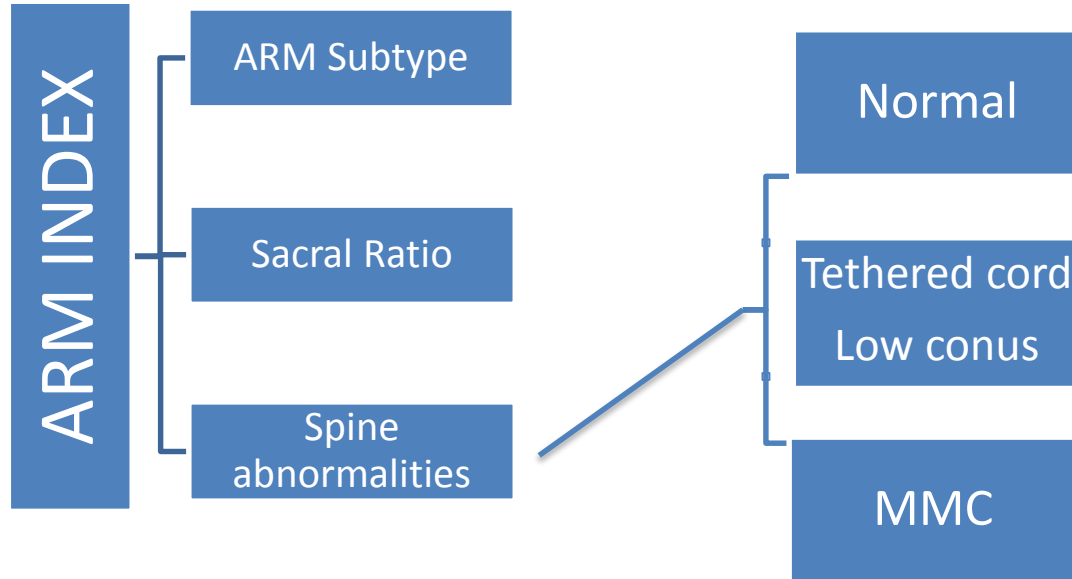


Normal Ratio:  $\frac{BC}{AB} = .74$



**NATIONWIDE CHILDREN'S**  
*When your child needs a hospital, everything matters.™*

# Methods

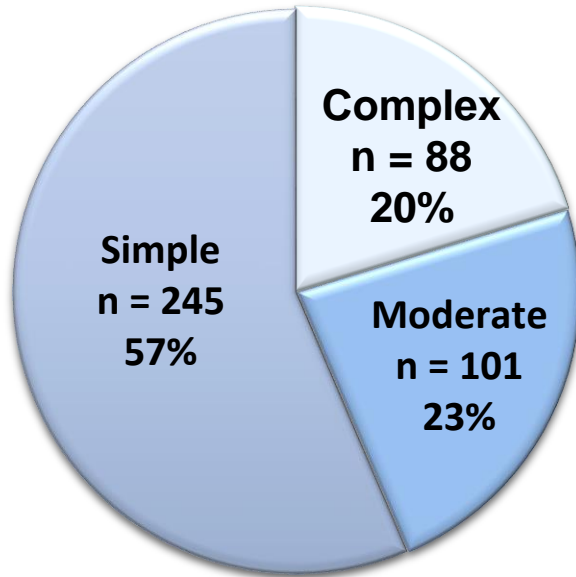


# Results

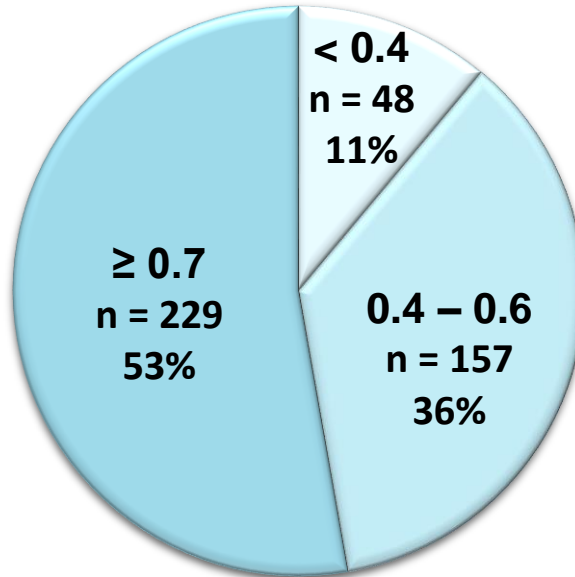
- $n = 434$
- 57.5% male ( $n = 251$ )
- Median age 8.4 yrs (IQR 6 – 12.3)

# Results

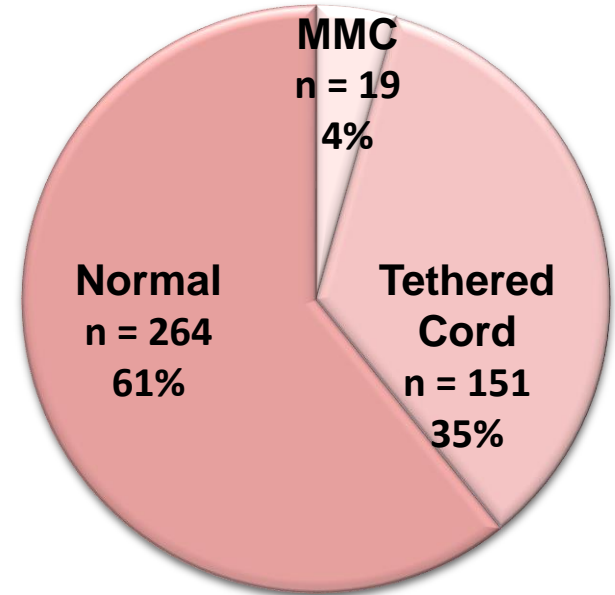
## ARM Severity



## Lateral Sacral Ratio

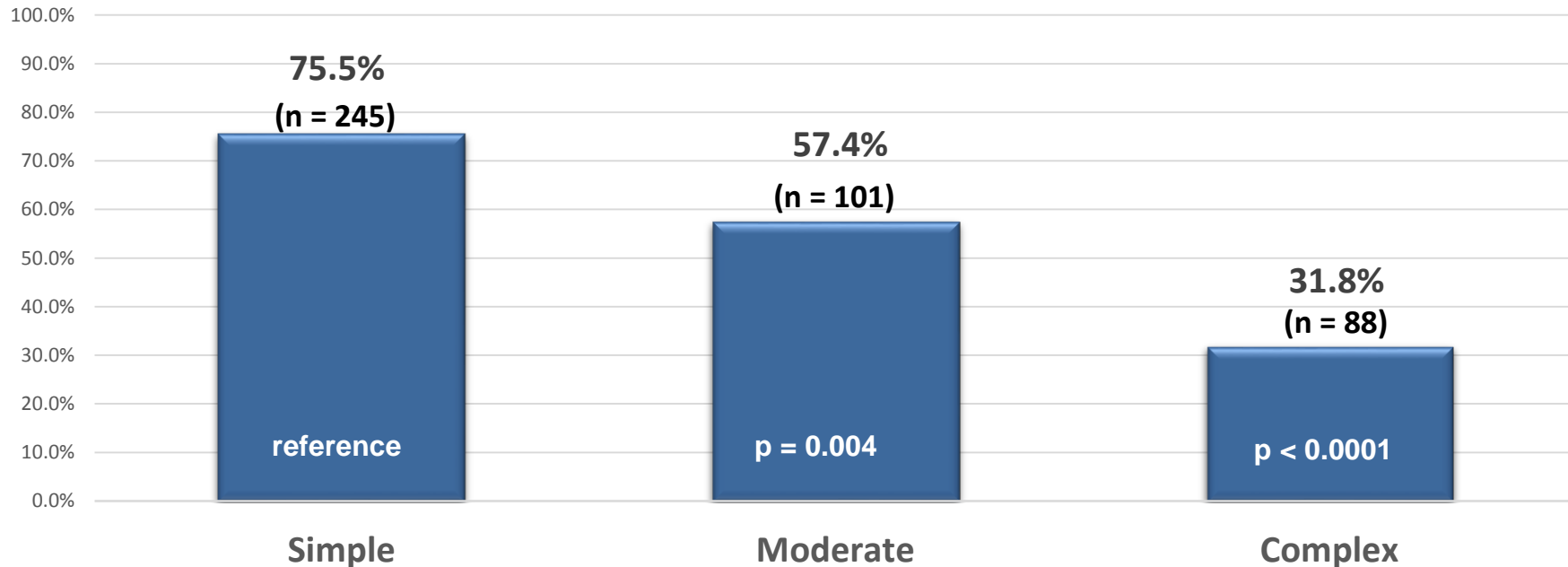


## Spinal Cord Findings



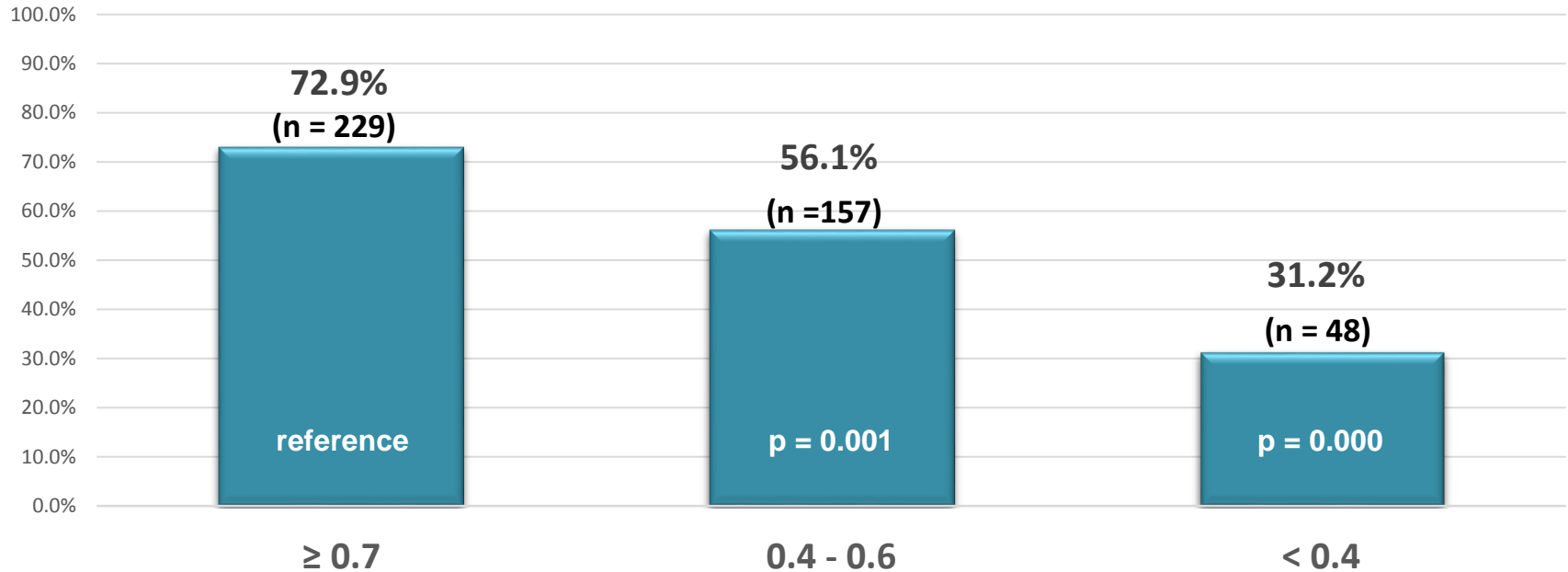
# Results

## Continence Rates ARM Severity



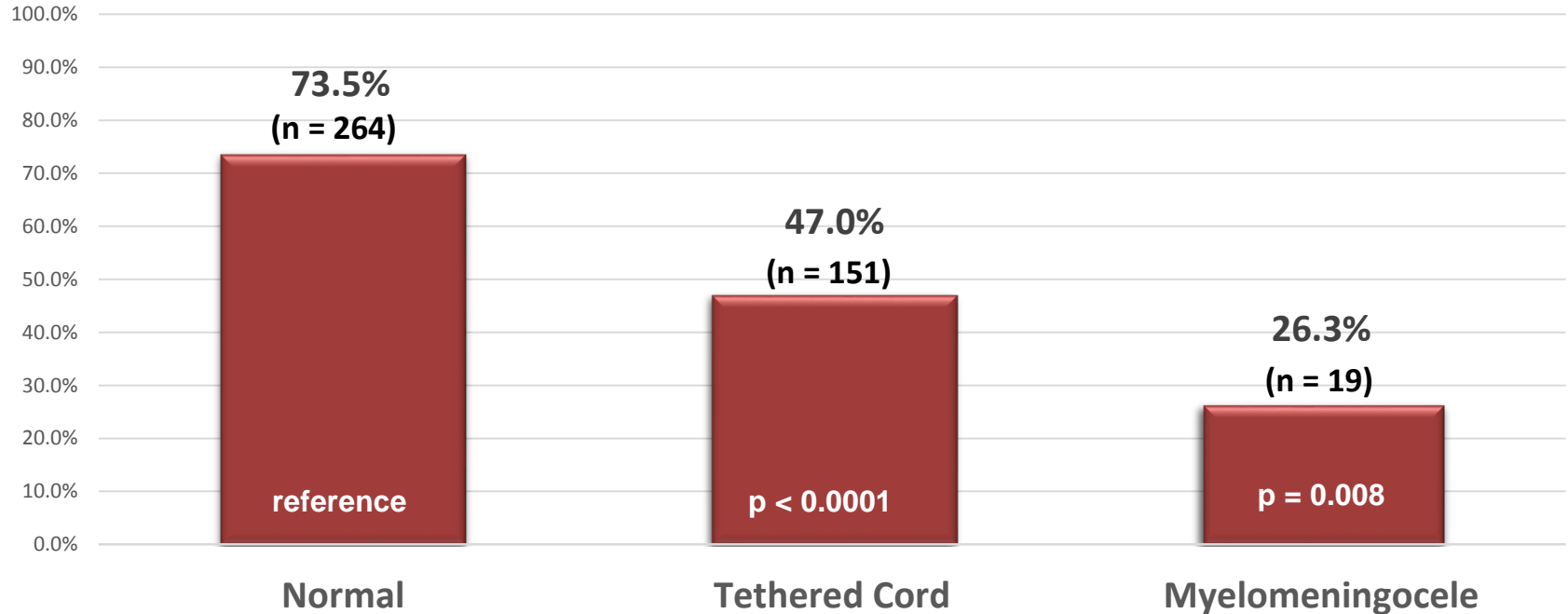
# Results

## Continence Rate By Sacral Ratio



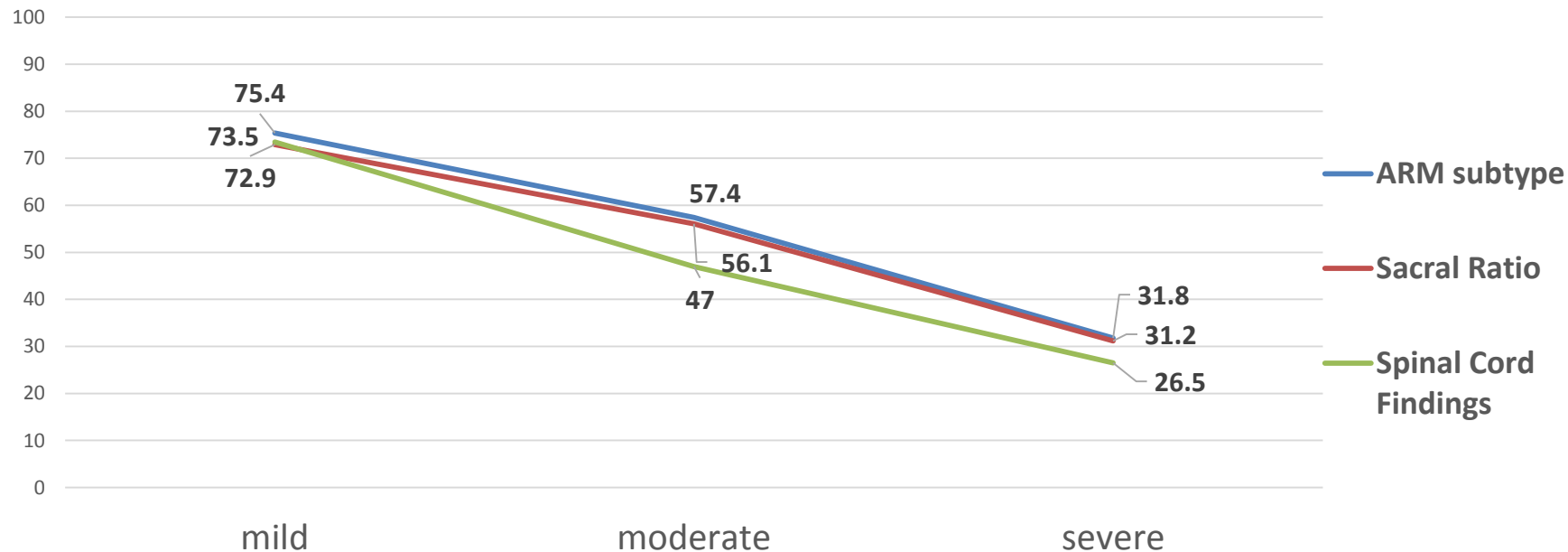
# Results

## Continence Rate By Spinal Cord Findings



# Summary of findings

## Summary of Results





# Future Directions

- Further analysis
  - Weighted influence of each anatomic factors
  - Determine which anatomic factor over rides the others
- Continence calculator based on ARM index

# Conclusion

- Anatomic factors are independently predictive of achieving urinary continence in ARM
  - ARM subtype
  - Lateral sacral ratio
  - Spinal abnormalities