

Intraoperative Laser Angiography in Bladder Exstrophy Closure

A Simple Technique to Prevent Catastrophic Penile Injury

**Martin Kaefer, Kahlil Saad, Patricio Gargollo, Benjamin Whittam
Richard Rink, Molly Fuchs, Diana Bowen, Rama Jayanthi
for the Pediatric Urology Midwest Alliance**



0022-5347/99/1624-1415/0

THE JOURNAL OF UROLOGY

Copyright © 1999 by AMERICAN UROLOGICAL ASSOCIATION, INC.

Vol. 162, 1415–1420, October 1999

Printed in U.S.A.

COMPLETE PRIMARY REPAIR OF EXSTROPHY

RICHARD W. GRADY AND MICHAEL E. MITCHELL

From the Department of Urology, Children's Hospital and Regional Medical Center, Seattle, Washington

Classic Bladder Exstrophy (N= 18)

Cloacal Exstrophy (N= 6)

18 performed on day one of life

Dry intervals (N=21)

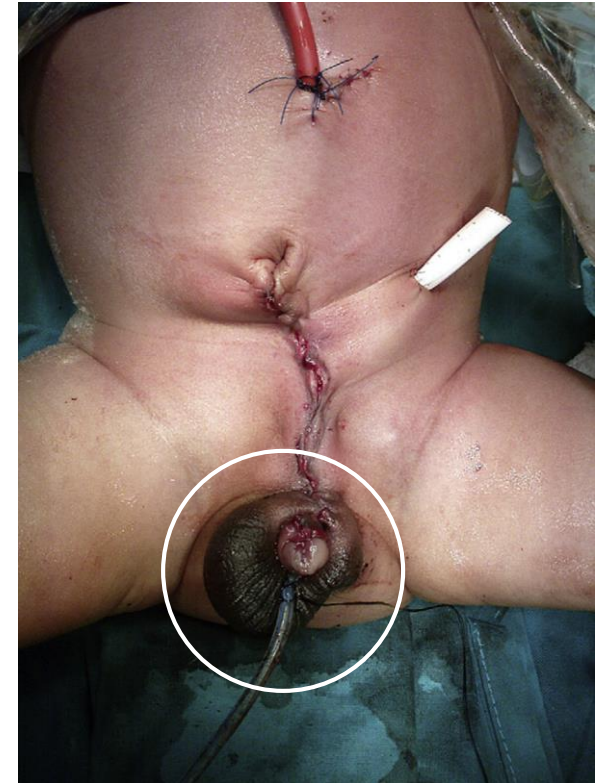Journal of Pediatric Urology (2009) 5, 519–520



Journal of
**Pediatric
urology**

CASE REPORT

Penile loss following complete primary repair of bladder exstrophy



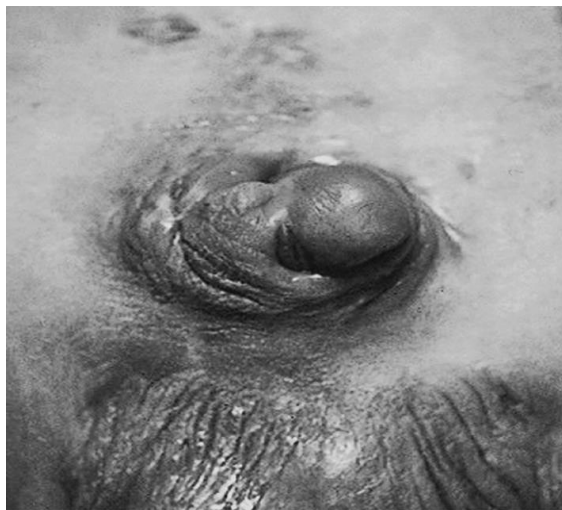

Figure 2 Right glanular atrophy following CPRE.

Potential Reasons

Direct Vascular Injury
Vasospasm
Compartment Syndrome

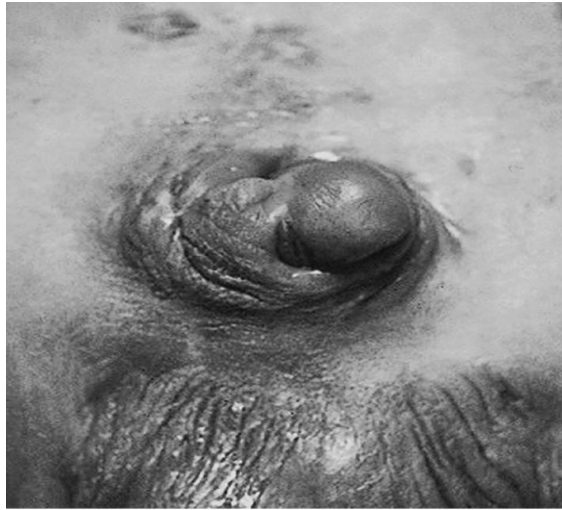

Figure 2 Right glanular atrophy following CPRE.

How to limit vascular compromise

Sound surgical technique

Adequate hydration

Neuroaxial blockade



PEDIATRIC UROLOGY
MIDWEST ALLIANCE

Algorithm

Dissection of Bladder and BN



Measure Penile Perfusion

(Intraoperative Laser Angiography)



Above Threshold



CPRE

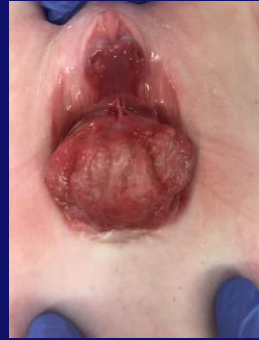

Below Threshold

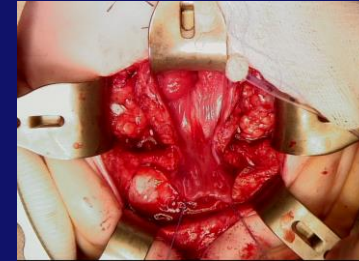


Staged Approach

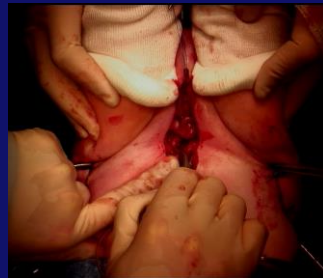Study



1) Beginning of Case

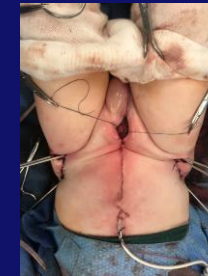

2) Initial Dissection

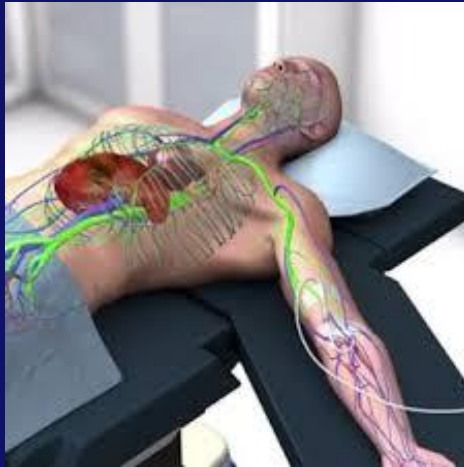

3) Pubis Together

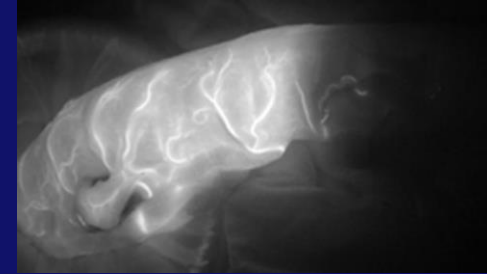
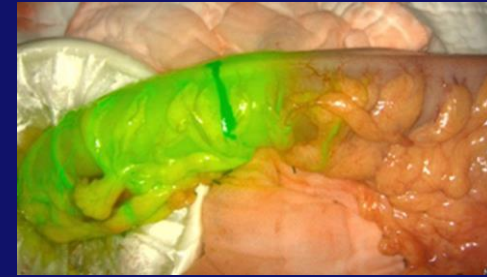
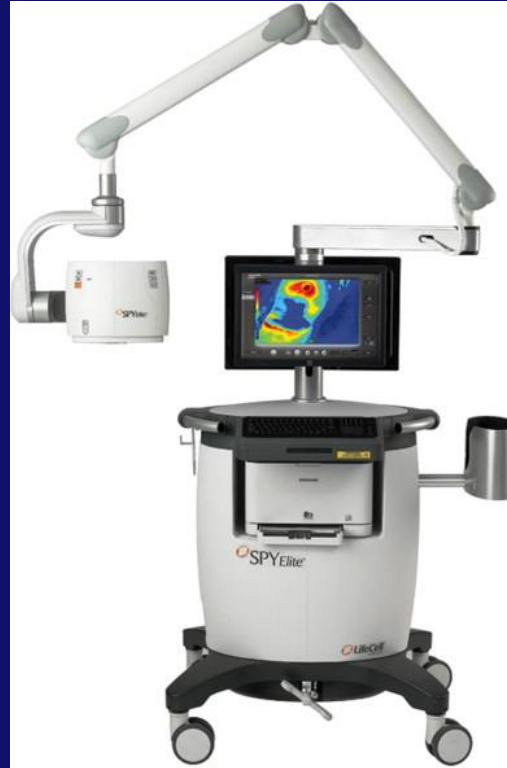CPRE ?
→
Staged ?



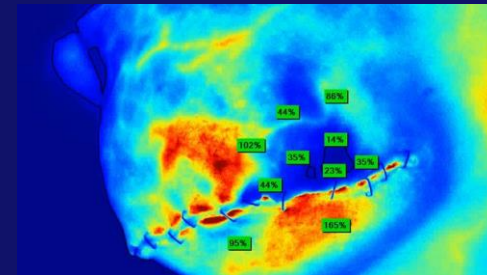
4) End of Case



**Indocyanine
Green**

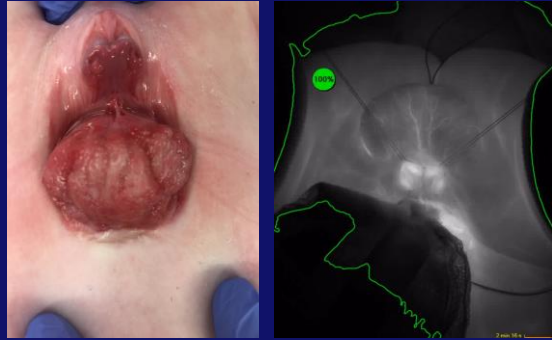


Ischemic Bowel



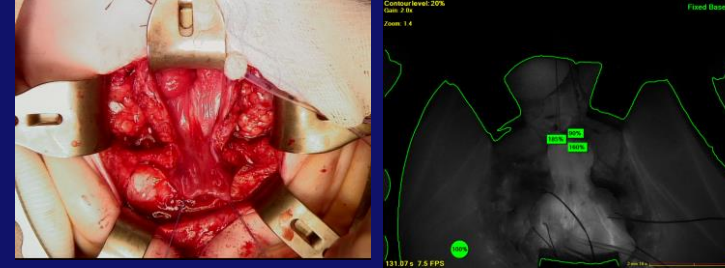
Breast Flap

Study (Surgeon is Blinded)



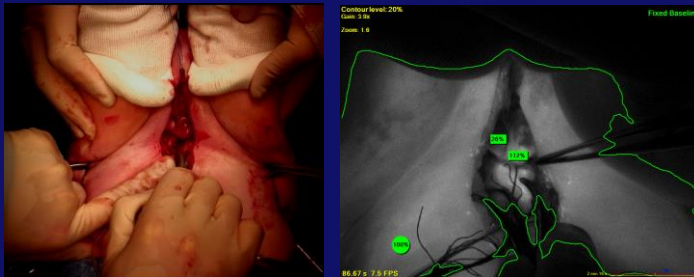
Study

1) Beginning of Case



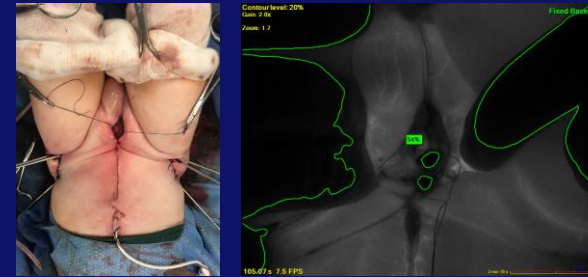
Study

2) Initial Dissection



Study

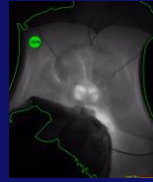
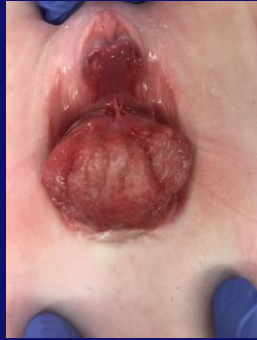3) Pubis Together



Study

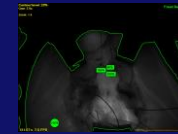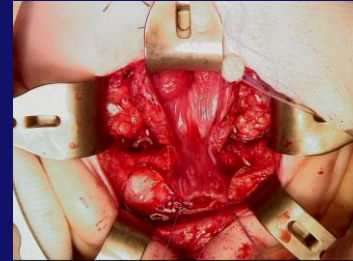
4) End of Case

Results (N=6 Male)



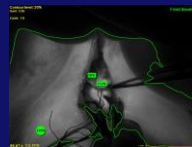
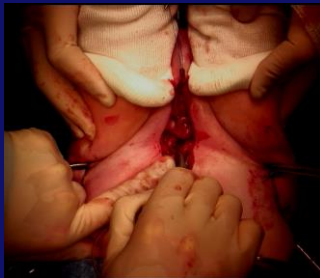341%

1) Beginning of Case



304%

2) Initial Dissection



128%

3) Pubis Together

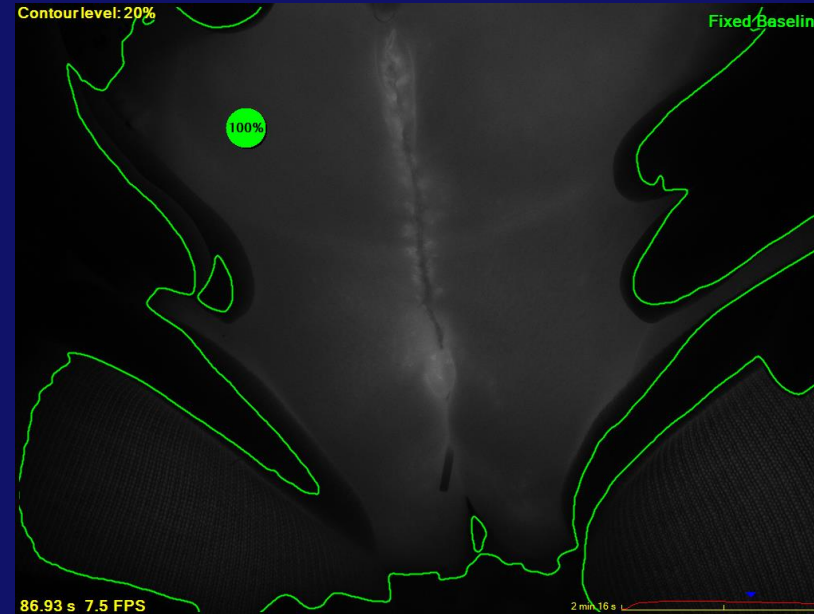
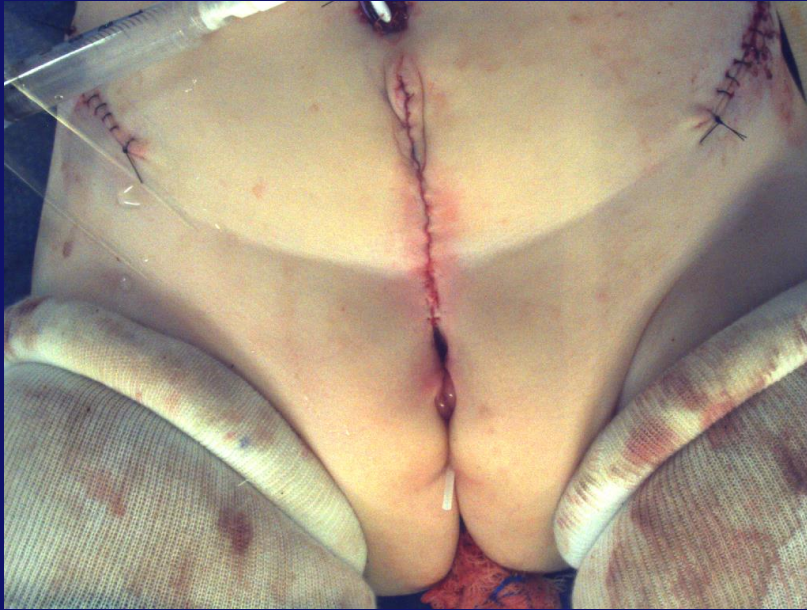
CPRE (4)

76.5%

Staged (2)

141%

4) End of Case



Female Exstrophy

Intraoperative Laser Angiography Conclusions

Easily to use

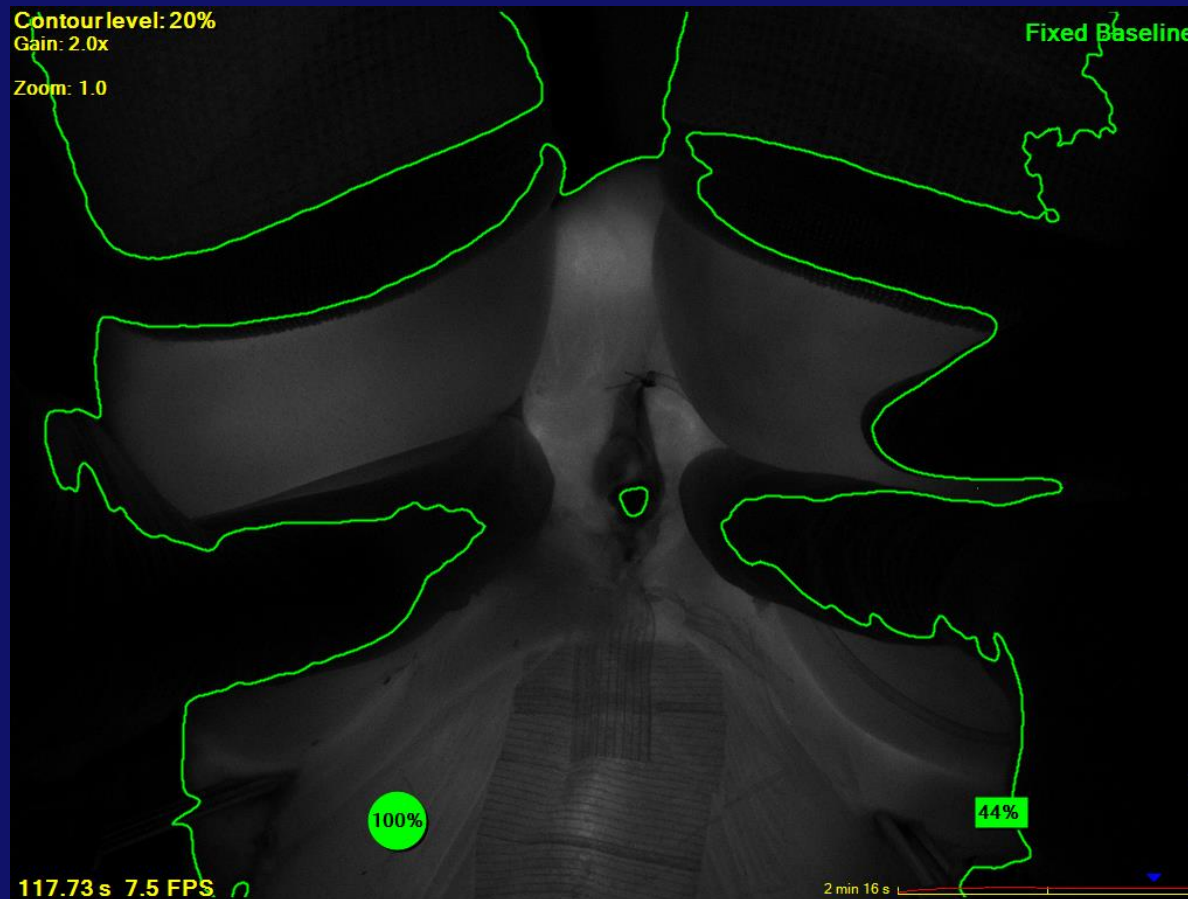
Penile Perfusion is reduced when pubis is apposed.

Marked reduction in penile blood flow may occur without any outward clinical signs.

In the immediate postoperative period, there may be greater reduction with CPRE as opposed to a staged repair.

Objectives

Prospective Evaluation of
Penile Viability
Penile Length and Width
Long Term Penile Function



Postoperative Day 1



Intraoperative Laser Angiography in Bladder Exstrophy Closure

A Simple Technique to Prevent Catastrophic Penile Injury

**Martin Kaefer, Kahlil Saad, Patricio Gargollo, Benjamin Whittam
Richard Rink, Molly Fuchs, Diana Bowen, Rama Jayanthi
for the Pediatric Urology Midwest Alliance**