

Unusual Presentation of Fusiform Megalourethra and Anterior Urethral Valves as a Transient Fetal Cystic Perineal Mass

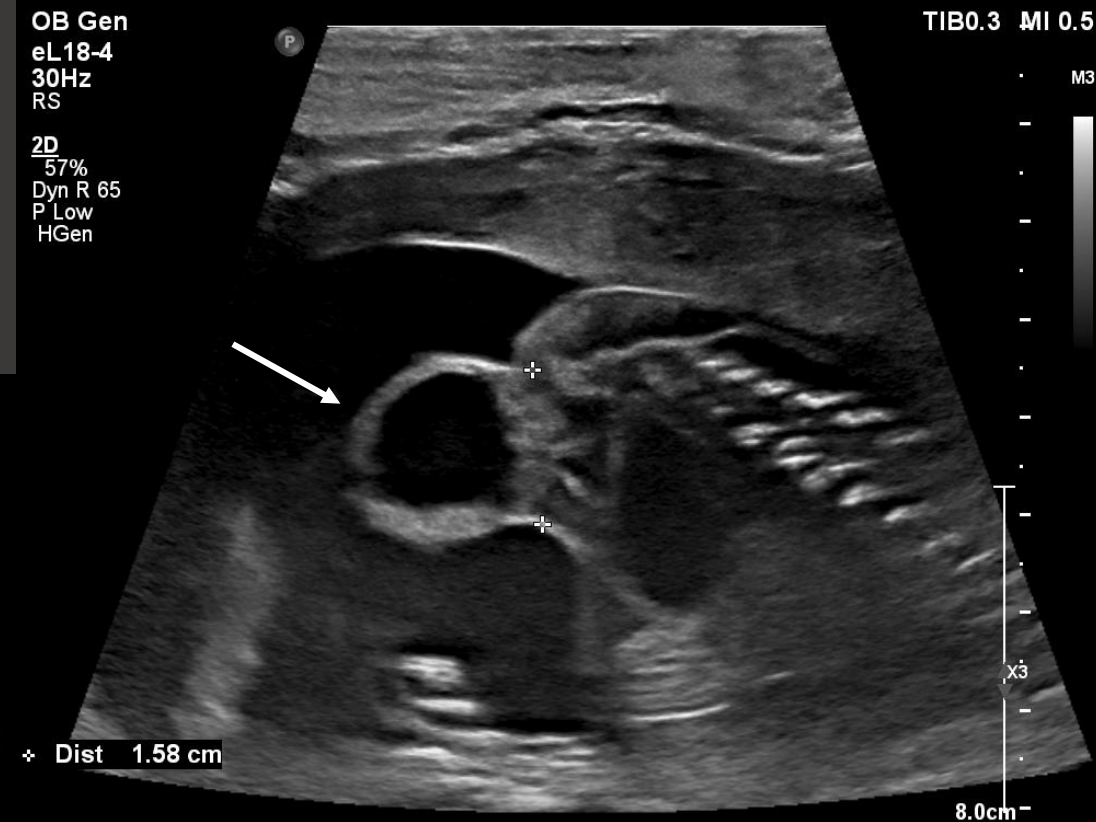
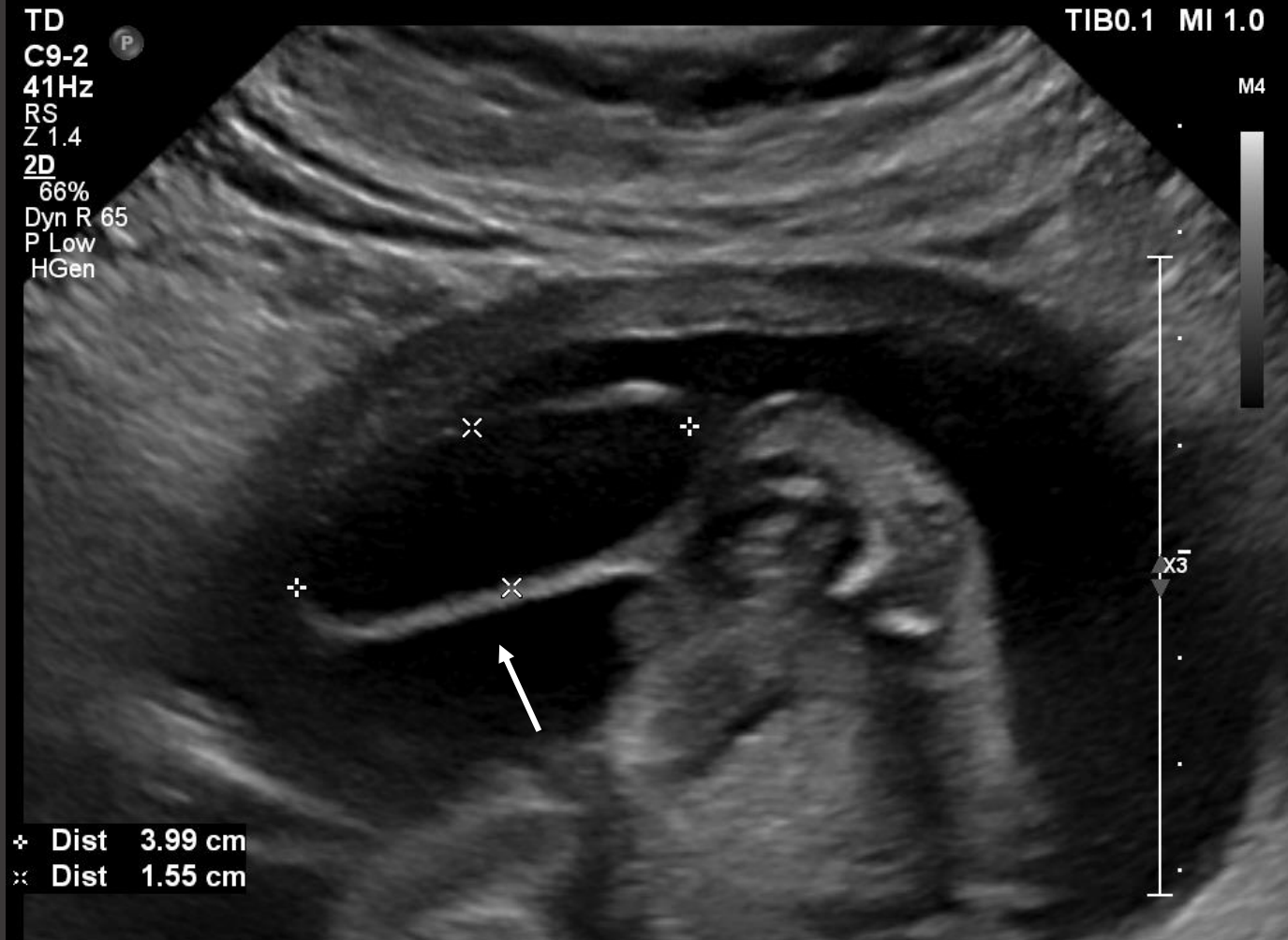Lauren E. Corona, MD

John M. Park, MD

University of Michigan, Department of Urology



28 yo G1P0 referred to fetal medicine for suspected sacrococcygeal teratoma at 20 weeks gestation



40x15x17mm cystic mass extending off perineum; no blood flow

Fetal MRI

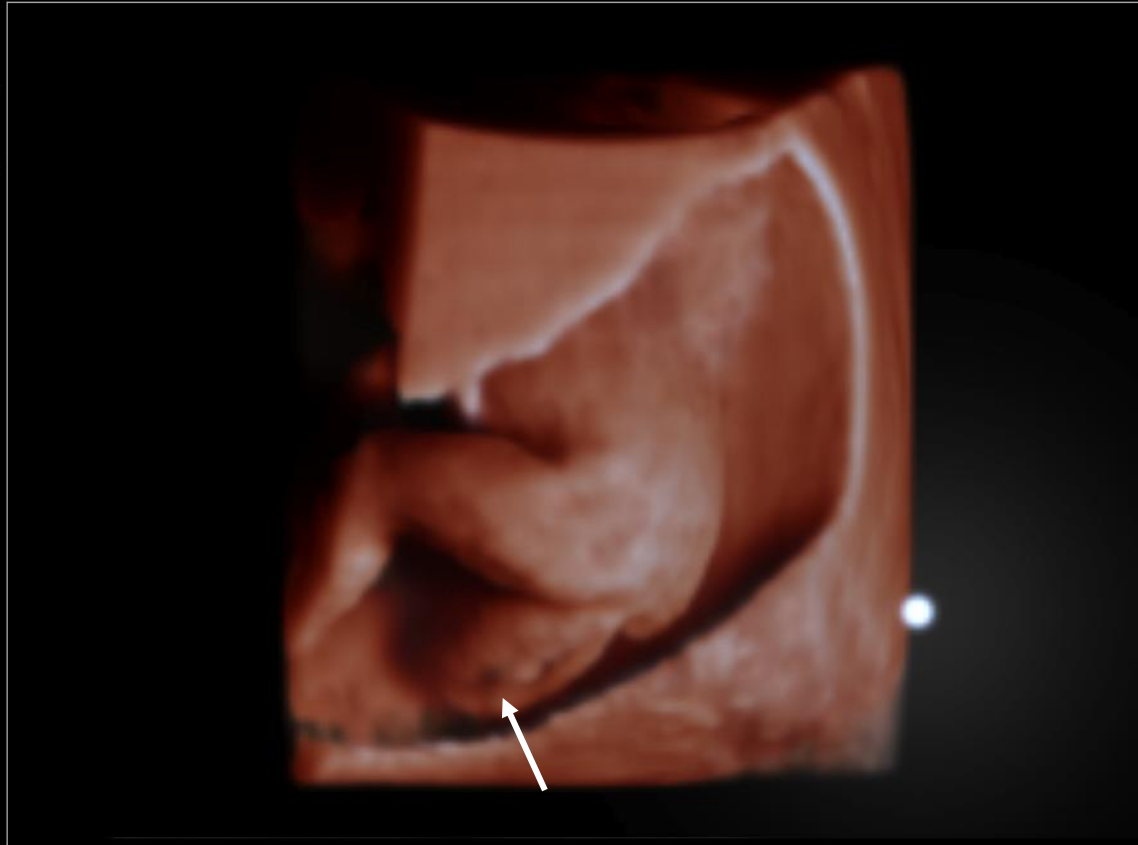
OB Gen
V6-2

TIB0.1 MI 0.0 OB Gen
V6-2

TIB0.1 MI 0.6

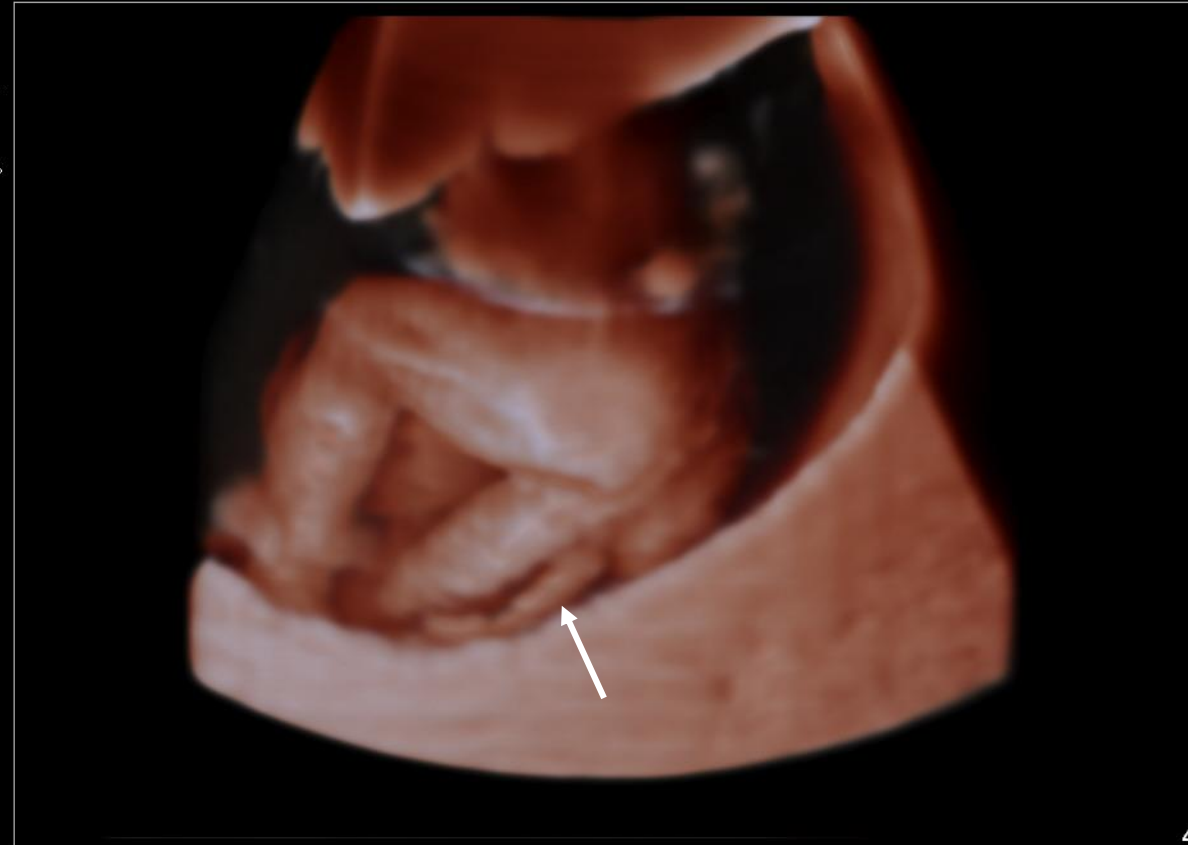
4D

Angle 55°
Vol Map 3
Vol Chr 4
MPR Map 3
MPR Chr Off
TrueVue
Thresh 0%
Transp 50%
Bright 40%
Lighting 30%
Smooth 50
XRES On

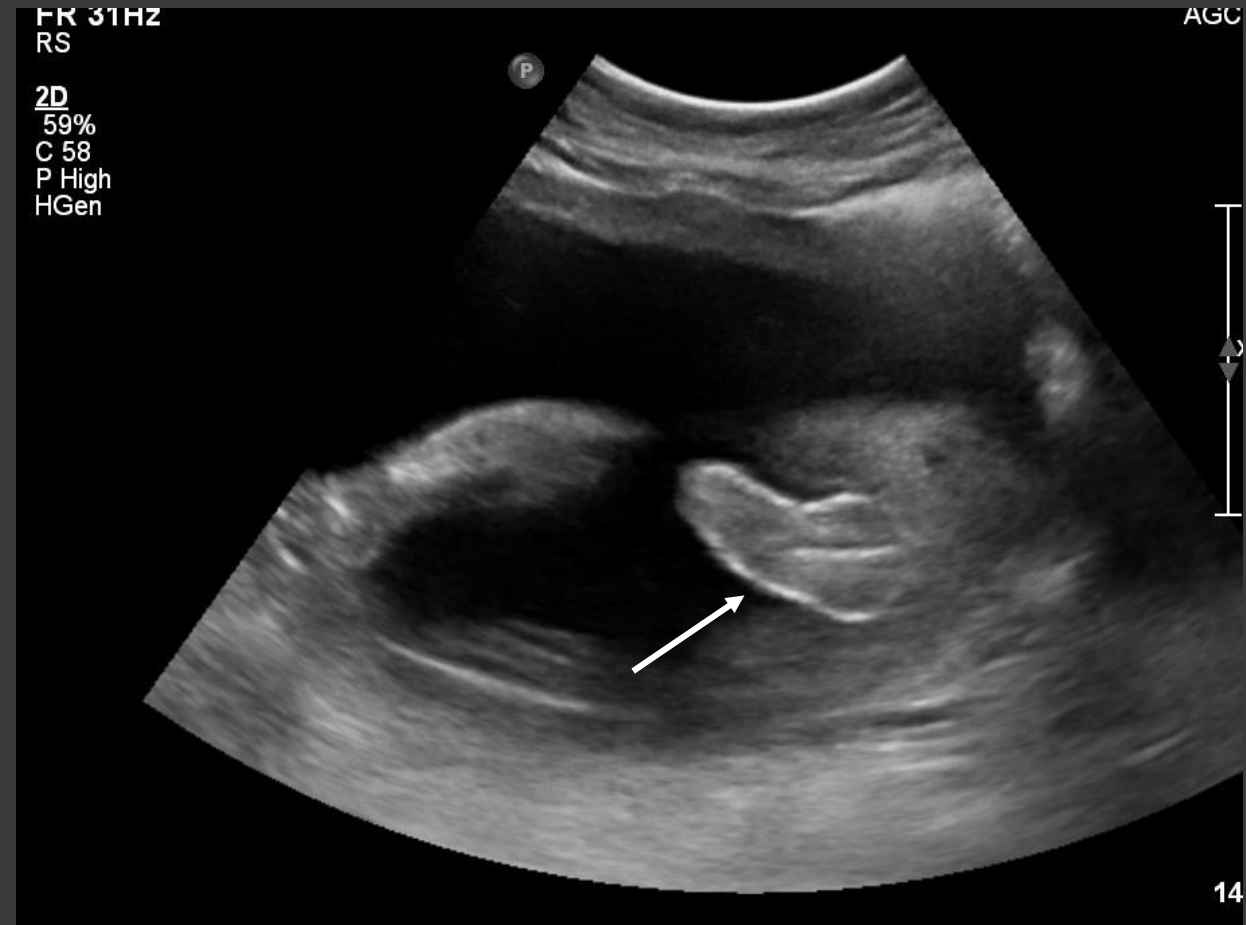
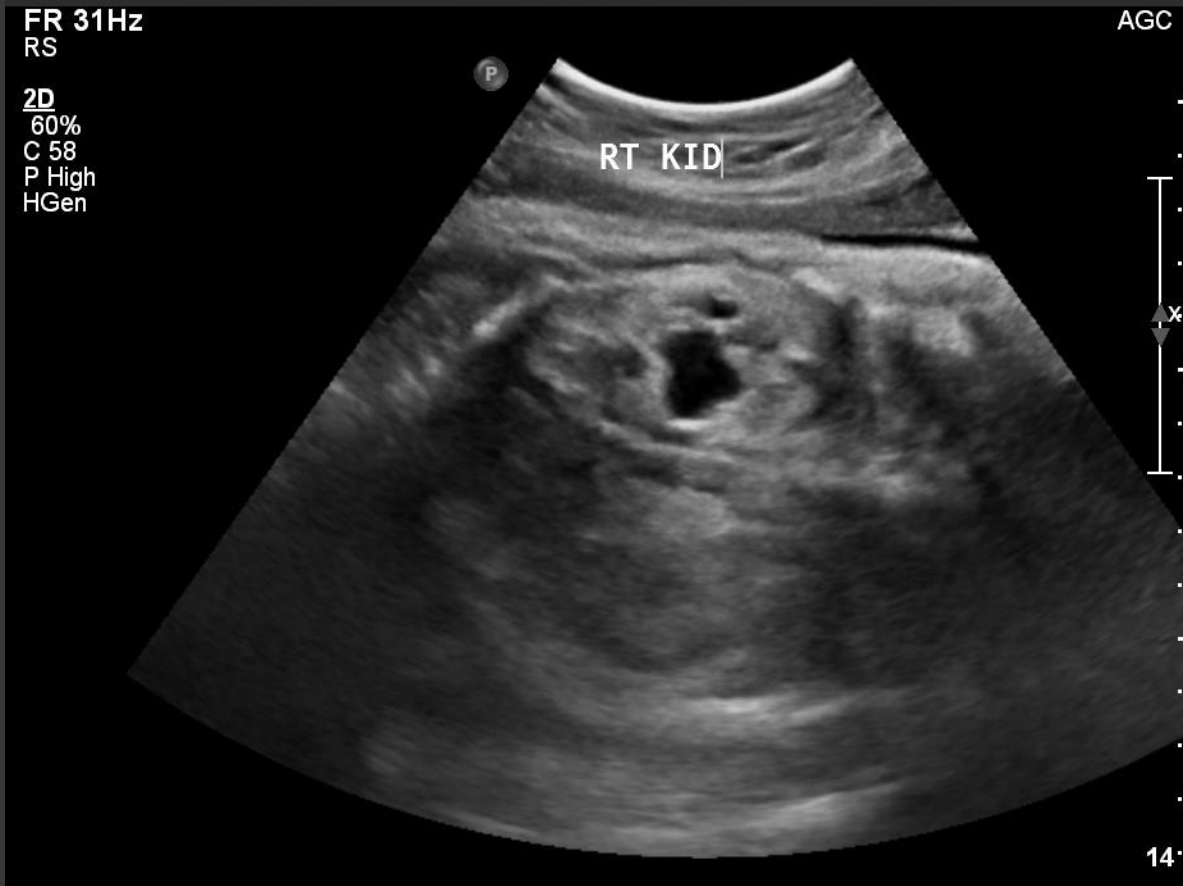

4D

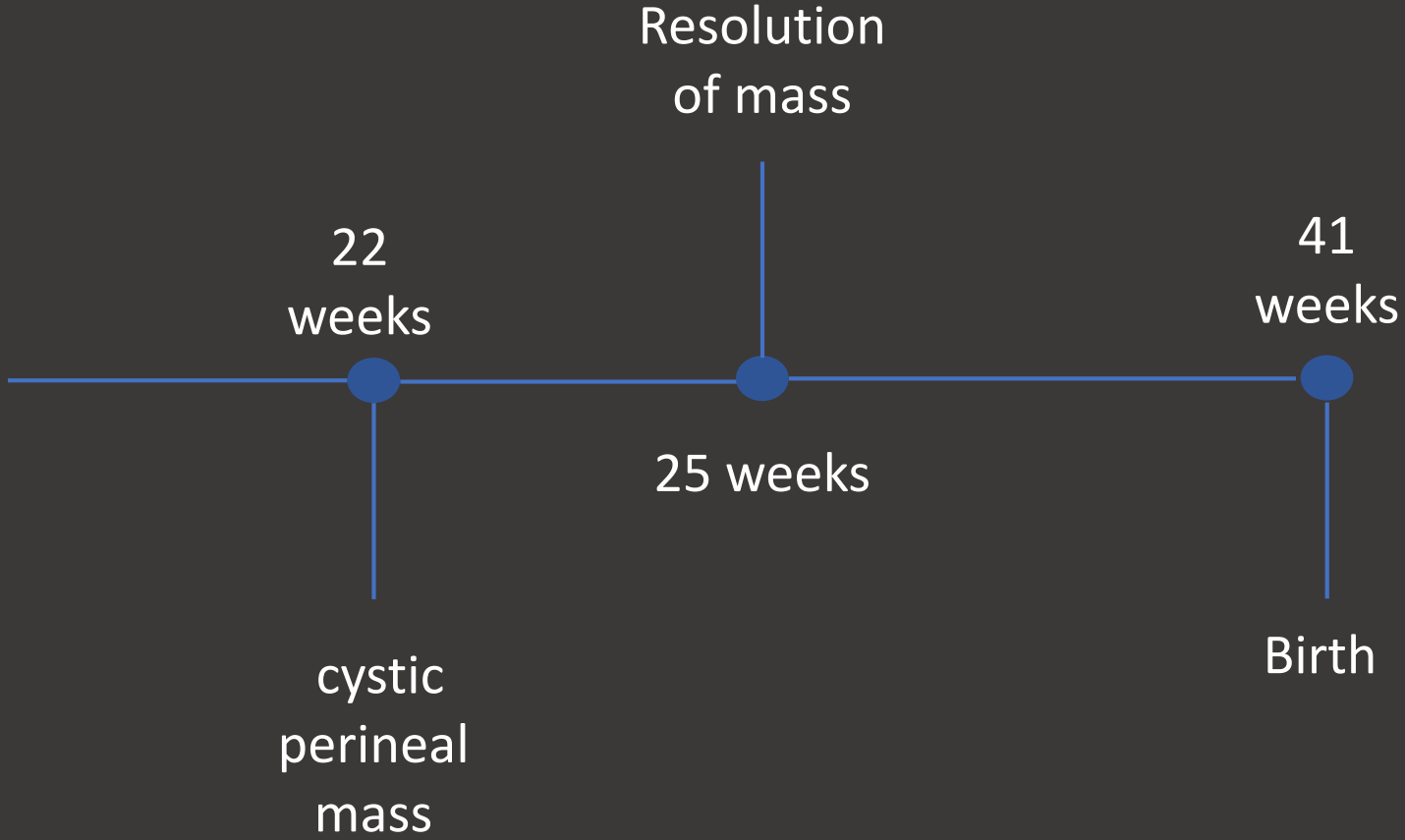
Angle 55°
Vol Map 3
Vol Chr 4
MPR Map 3
MPR Chr Off
TrueVue
Thresh 0%
Transp 50%
Bright 40%
Lighting 30%
Smooth 50
XRES On

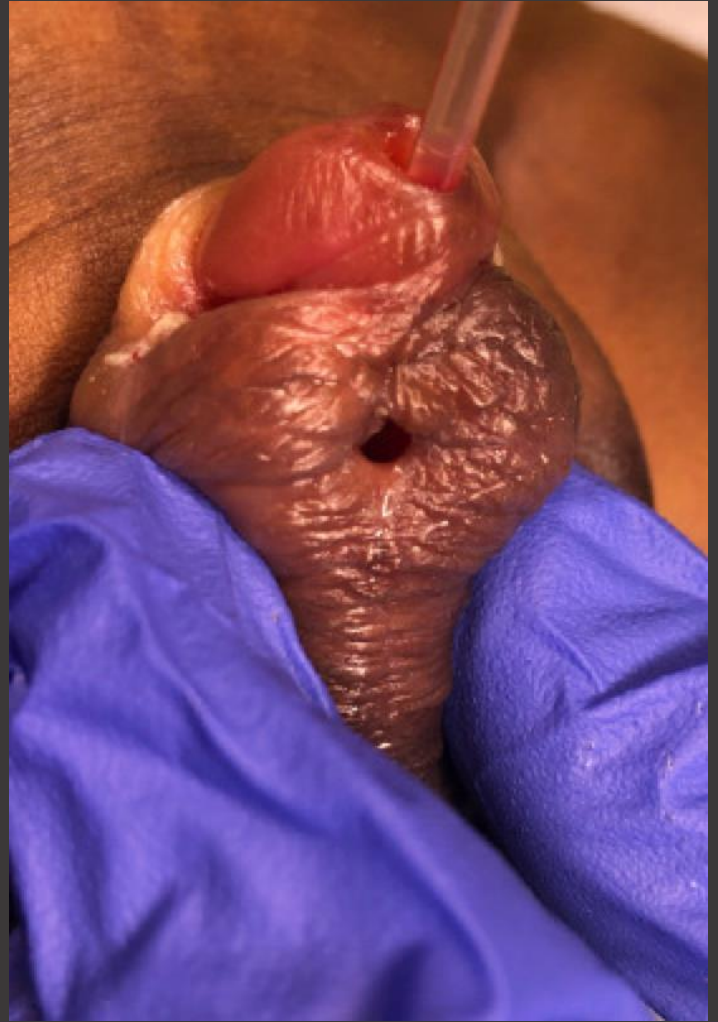
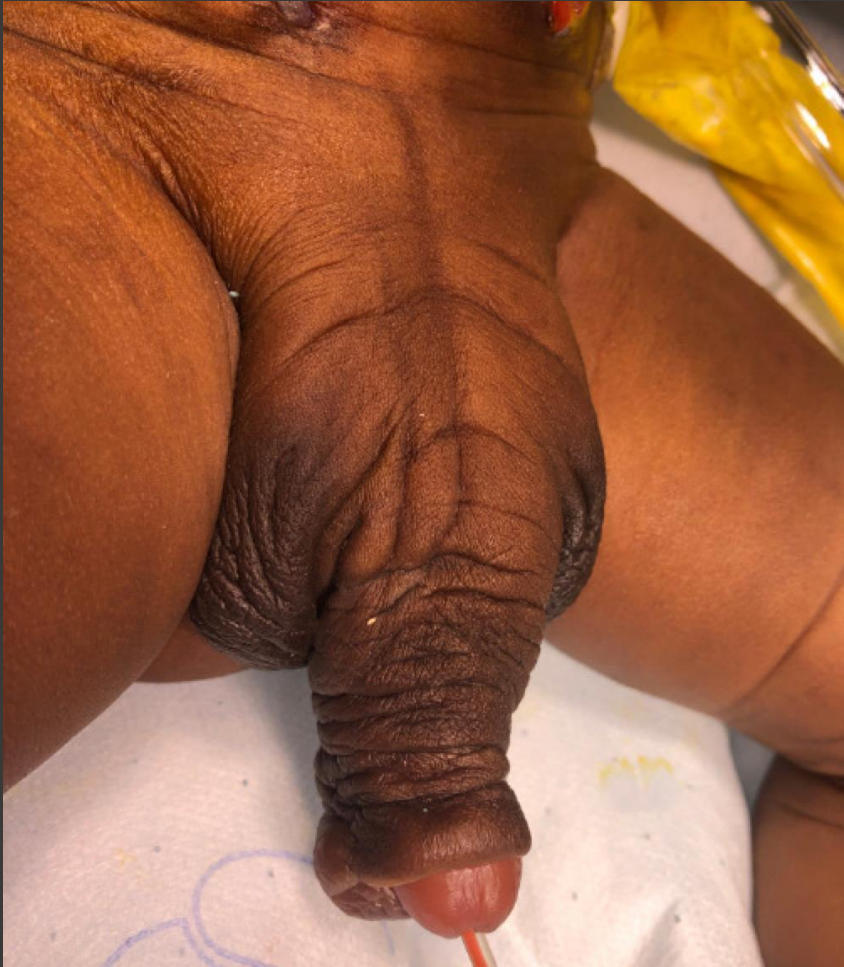
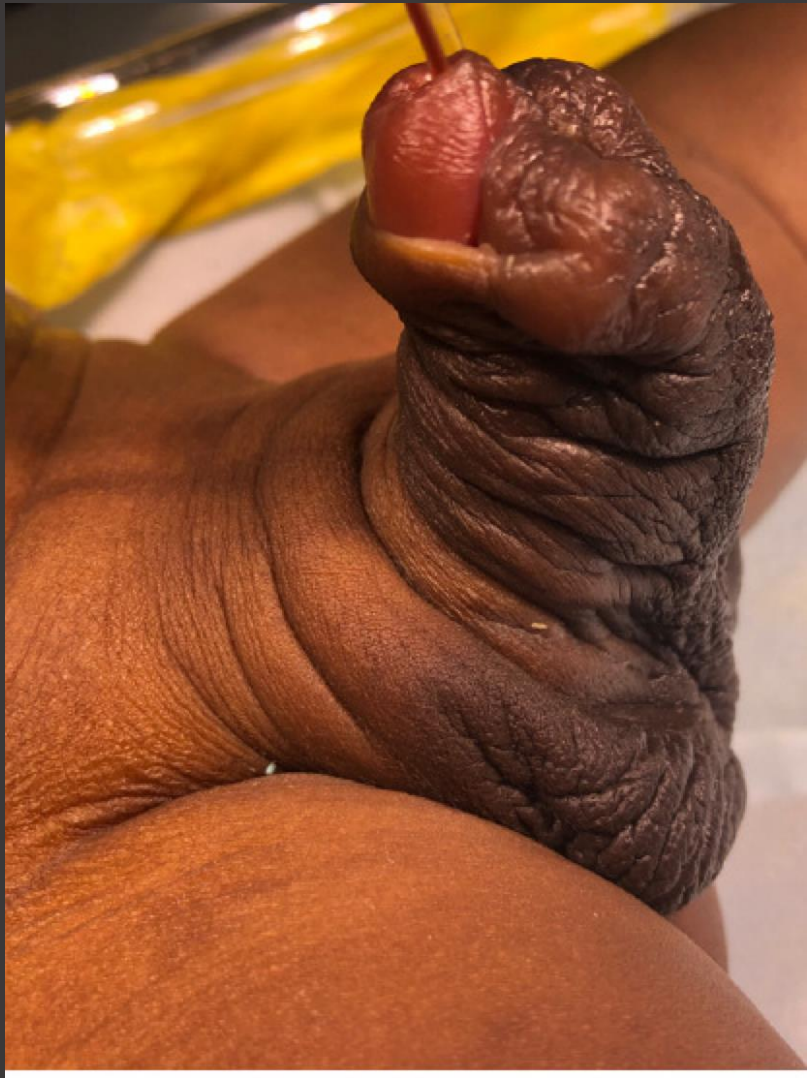
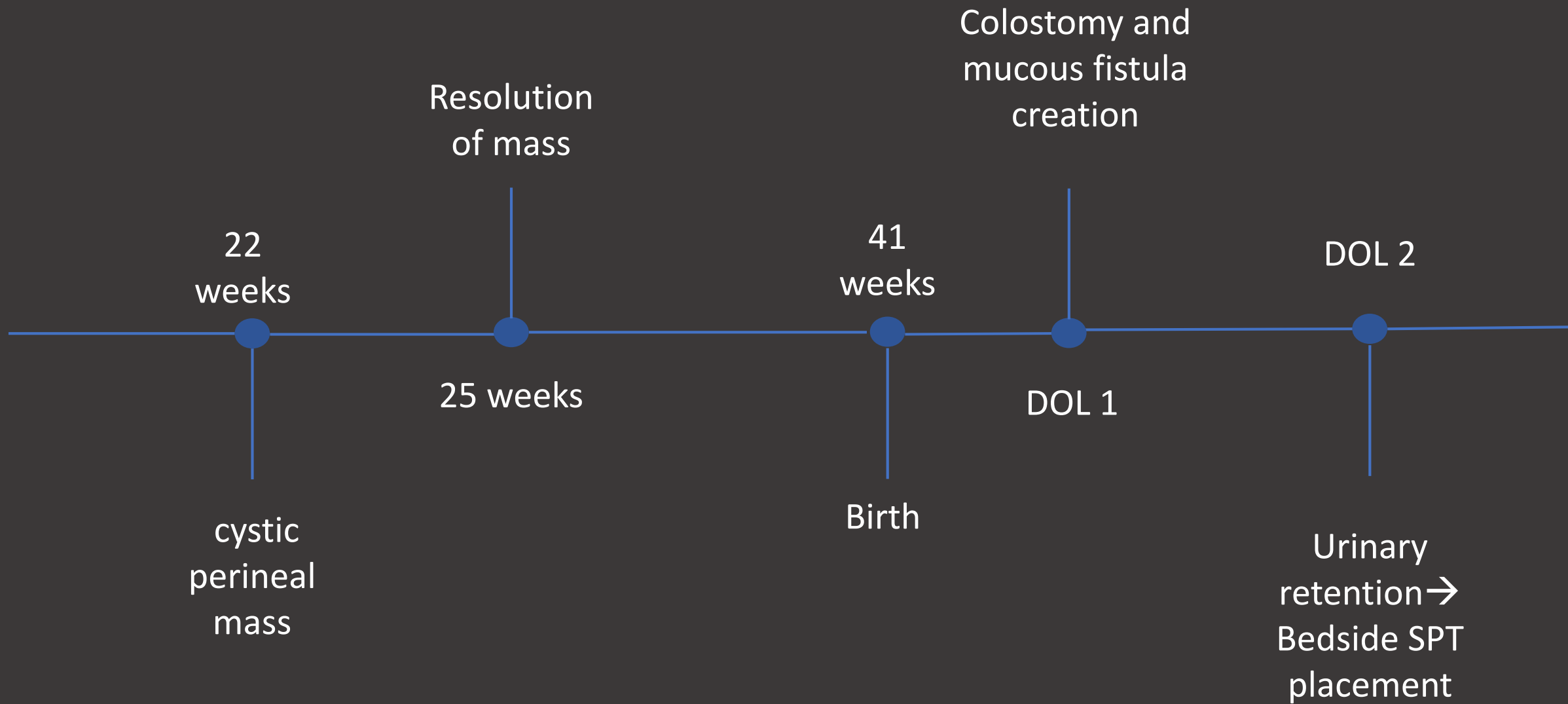
- Repeat scan at 25 weeks showed resolution of mass
- Cell free DNA consistent with XY



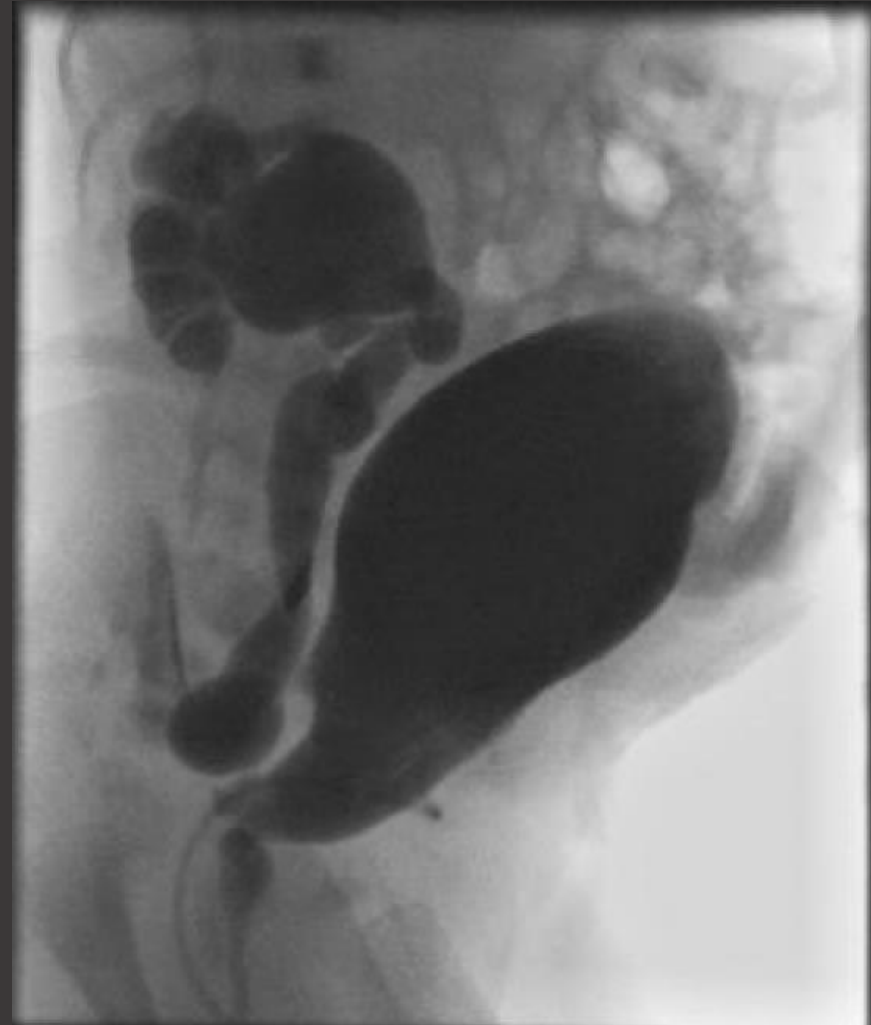
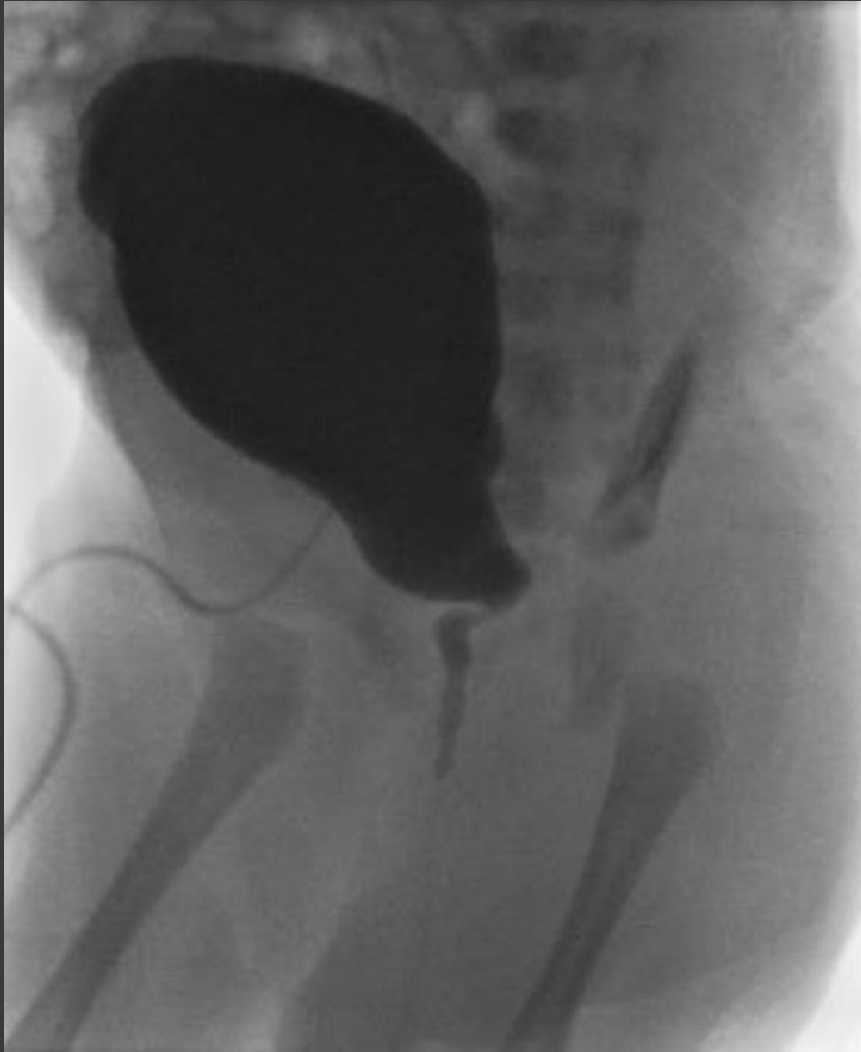- Continued normal growth throughout pregnancy
- Moderately dilated right pelvis







VCUG (two weeks of life)

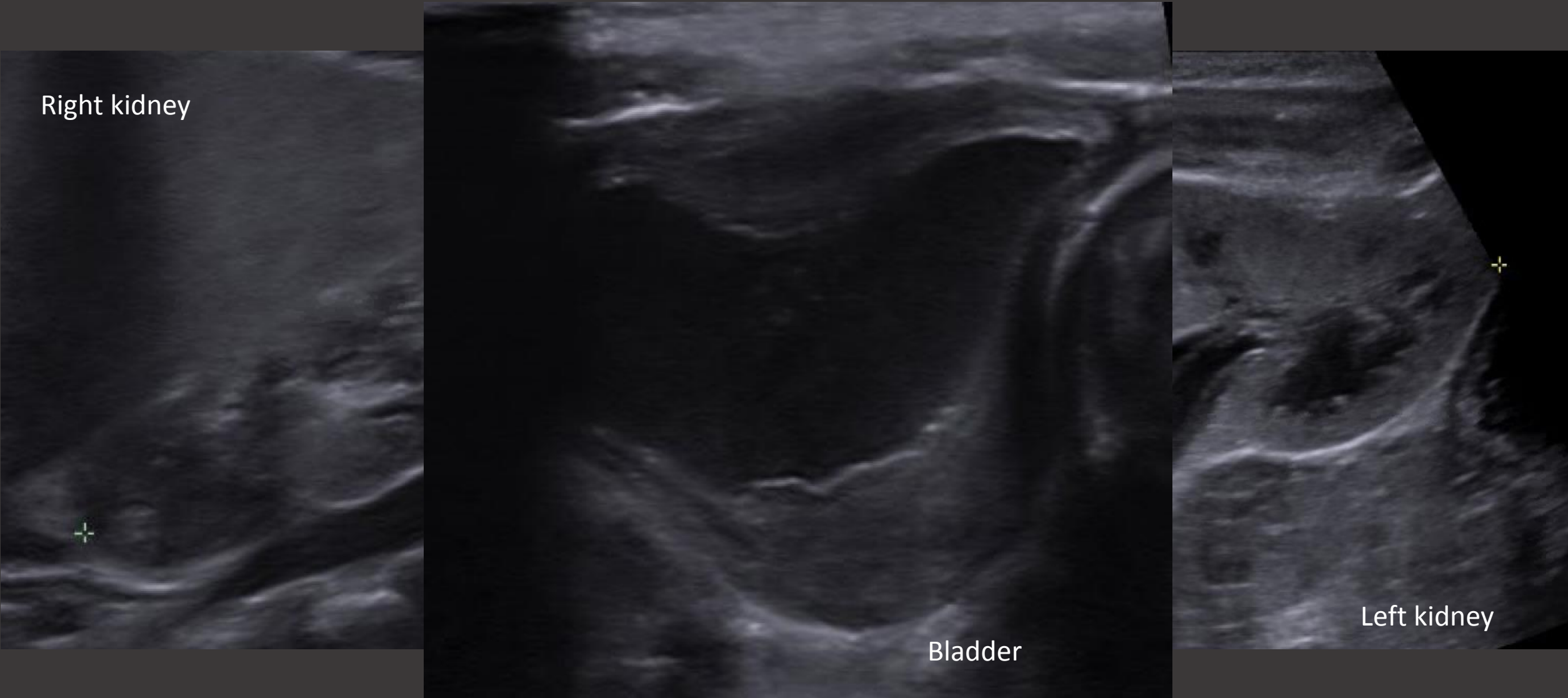


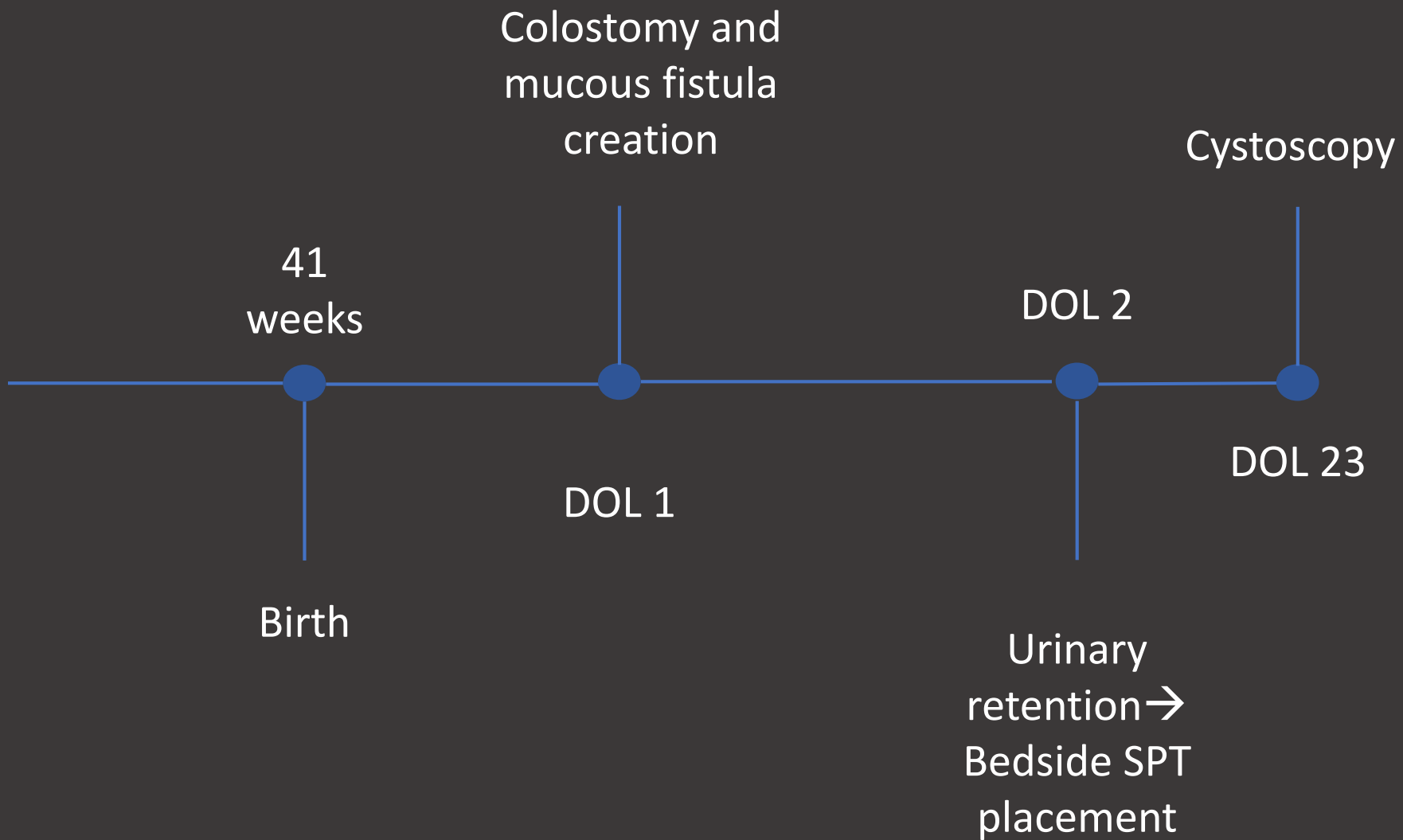
Right kidney

Bladder

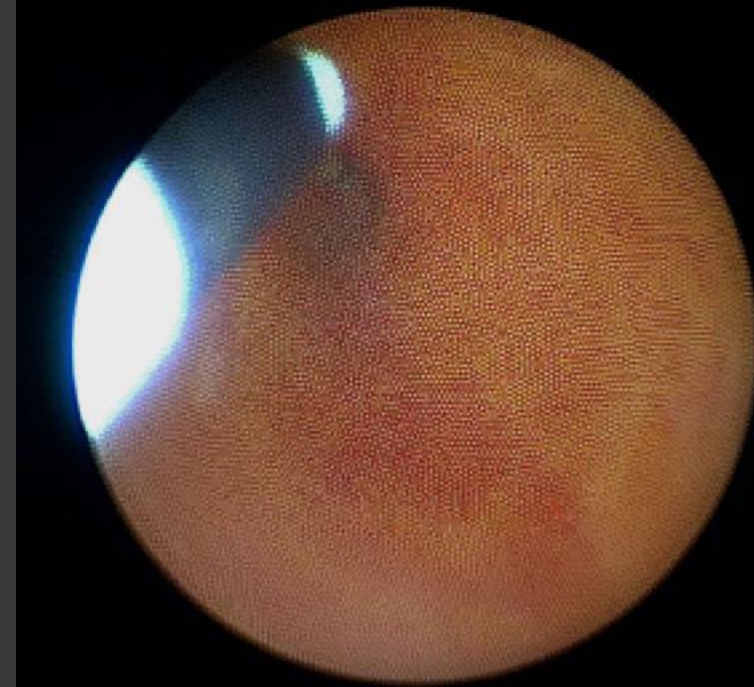
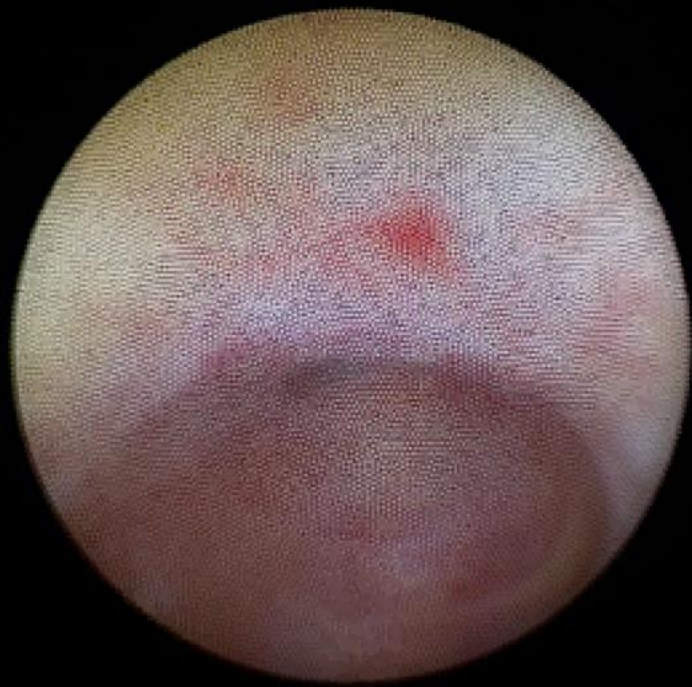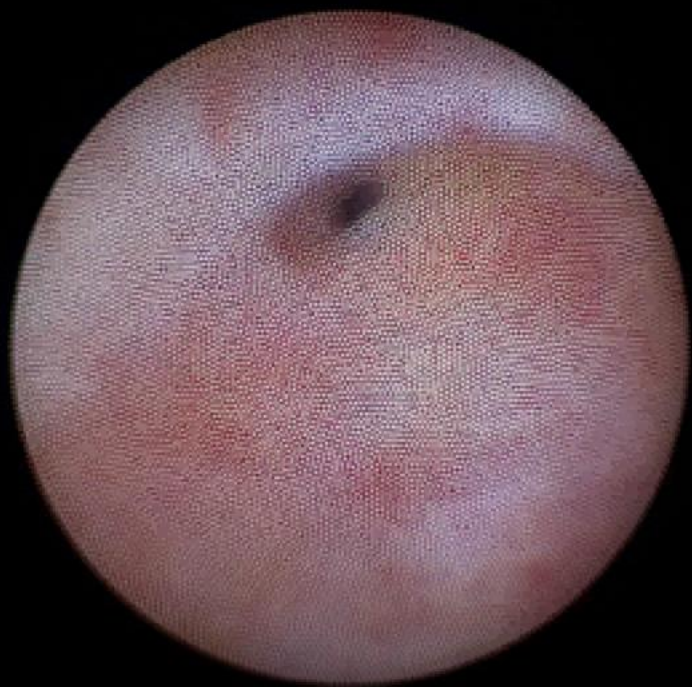Left kidney

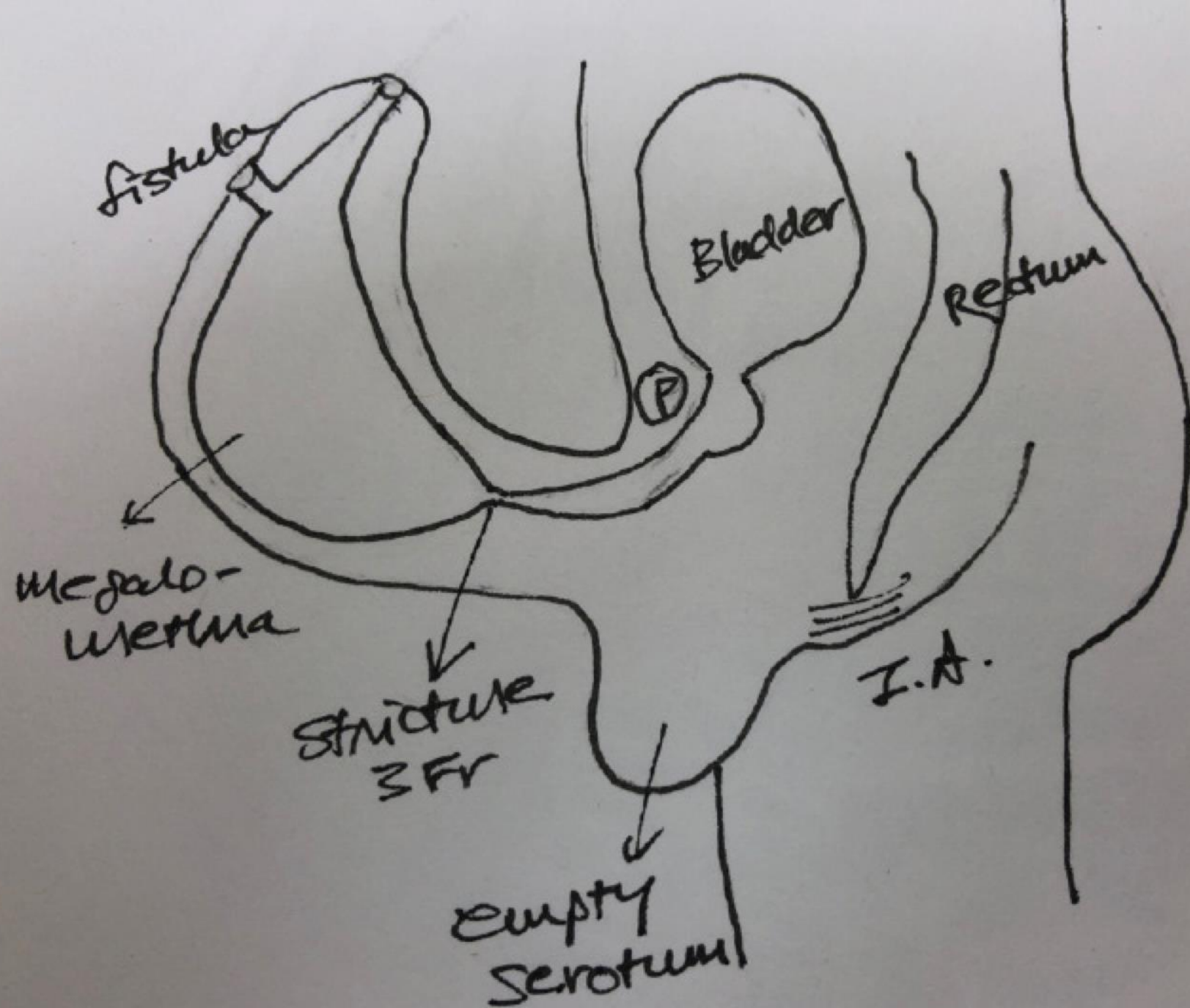
Renal ultrasound (3 weeks of life)

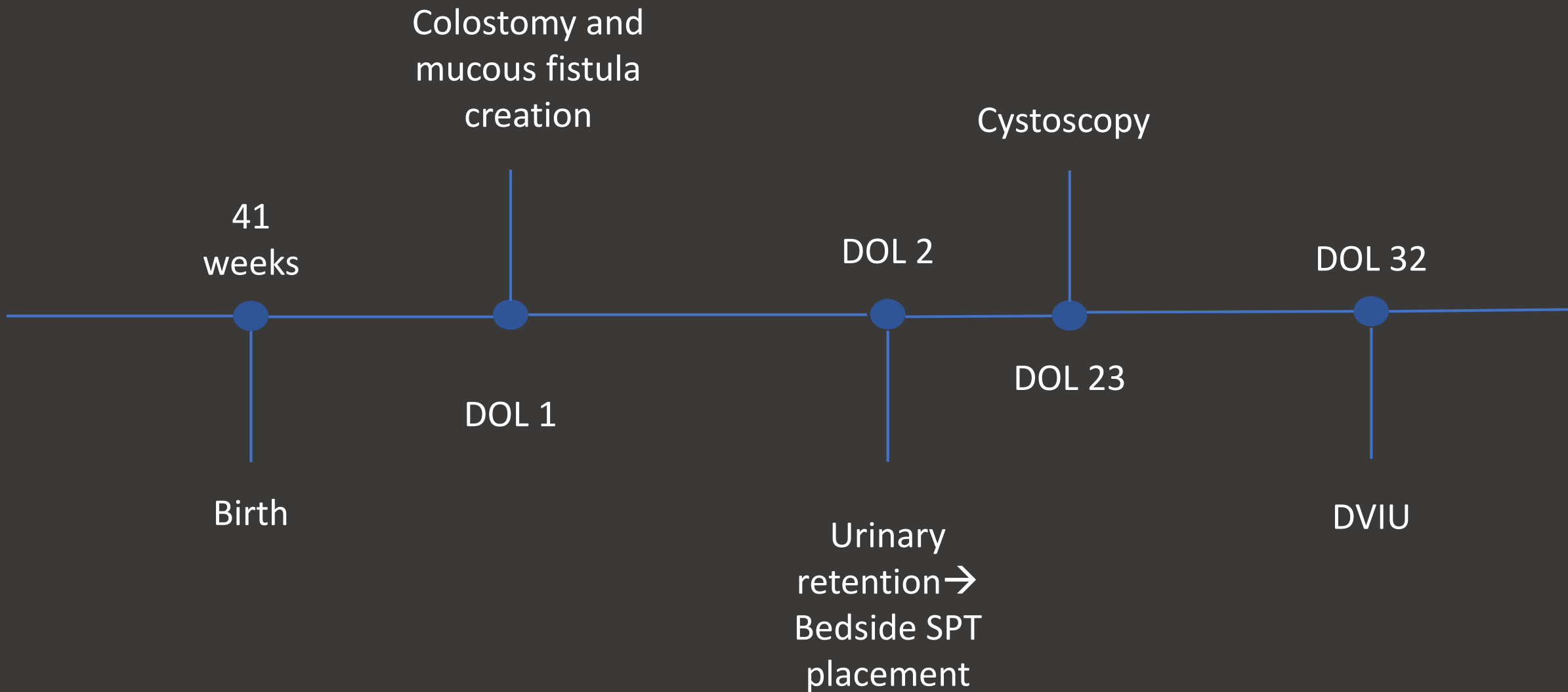


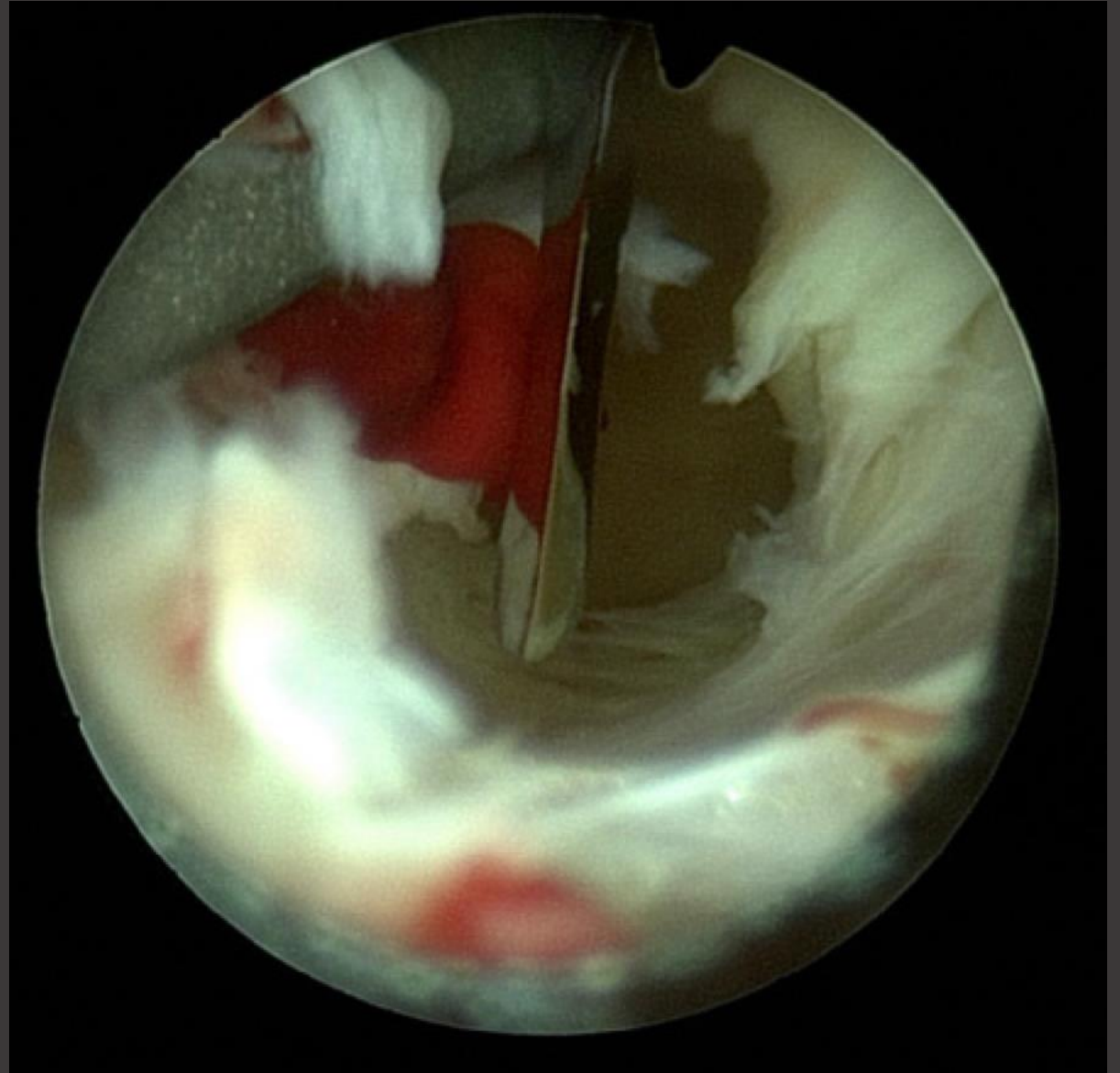
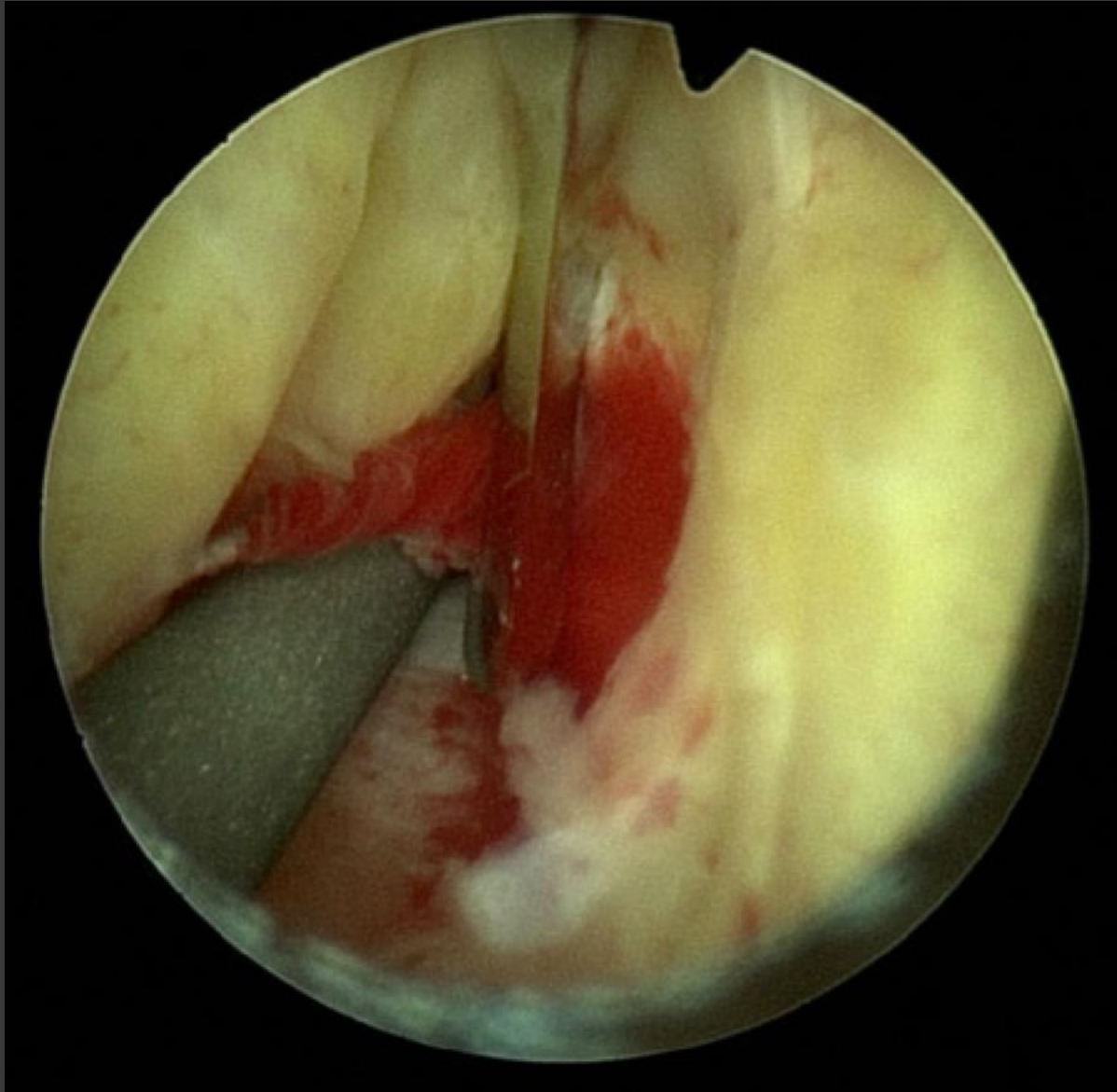


Urethroscopy



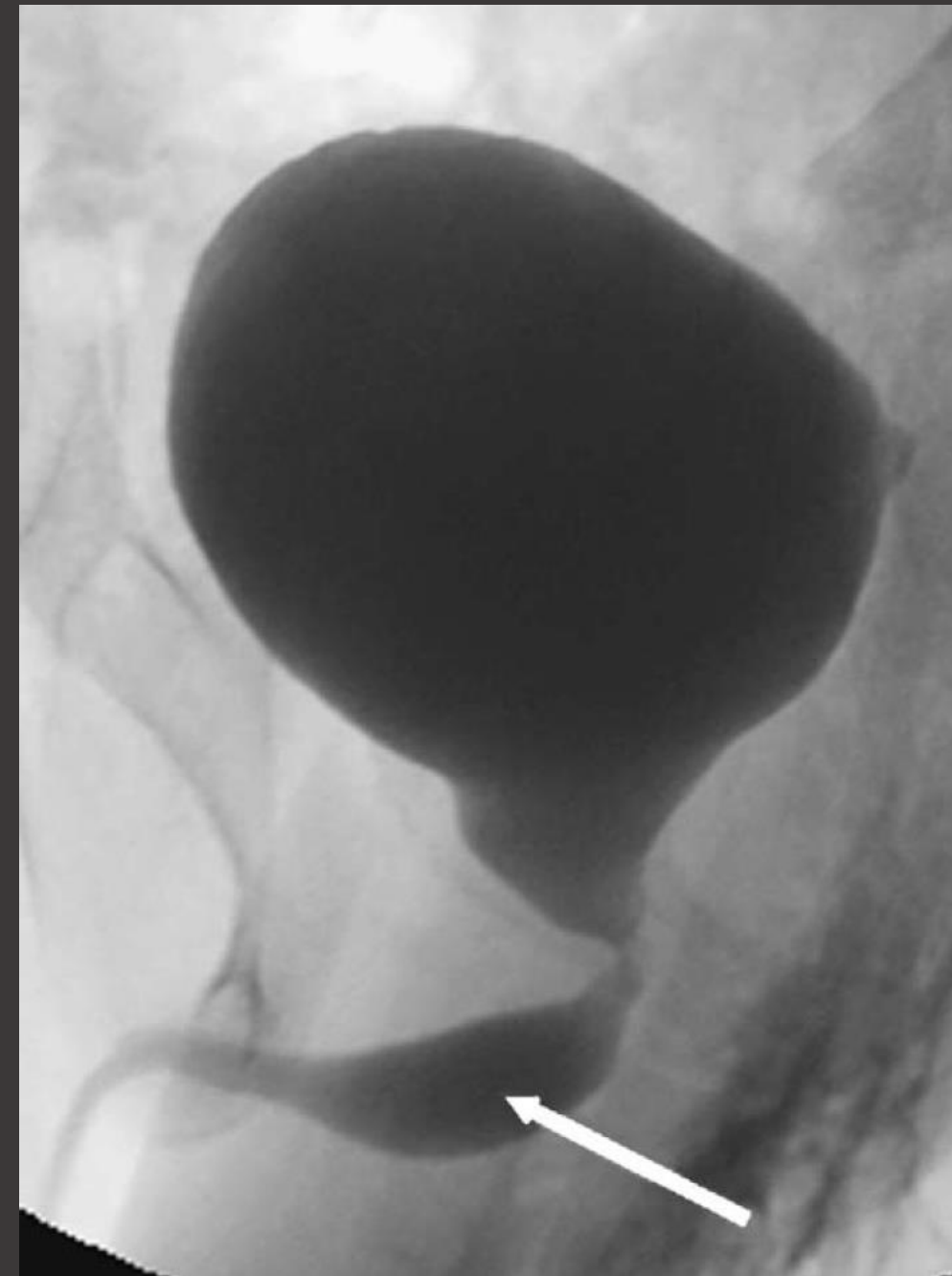






Megalourethra

- Scaphoid
 - Ventral dilatation and hypoplasia of the corpus spongiosum
- Fusiform
 - Circumferential urethral dilatation and hypoplasia of the corpus spongiosum and corpora cavernosa
- Associated with cryptorchidism, renal agenesis, hypospadias, primary megaureter, PBS, VACTERL, GI anomalies



Conclusion

- Normal voiding per urethra
- Prophylactic antibiotics for right lower pole reflux
- Future: Urethral and phallic reconstruction along with orchidopexy

Thank You

Questions?



