

A patient with bilateral single-system ectopic ureters who achieved urinary continence after ureteral reimplantation



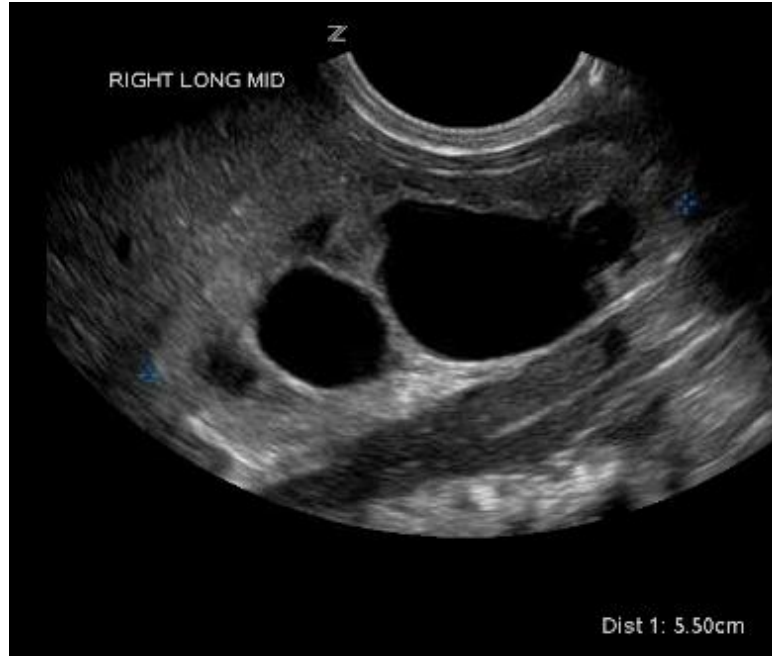Kristin M. Ebert, MD; Rama Jayanthi, MD
Nationwide Children's Hospital

Background

- Born at 36 weeks gestation
- VATER syndrome
- Prenatal ultrasound
 - Unilateral right hydronephrosis
 - Concern for absent bladder

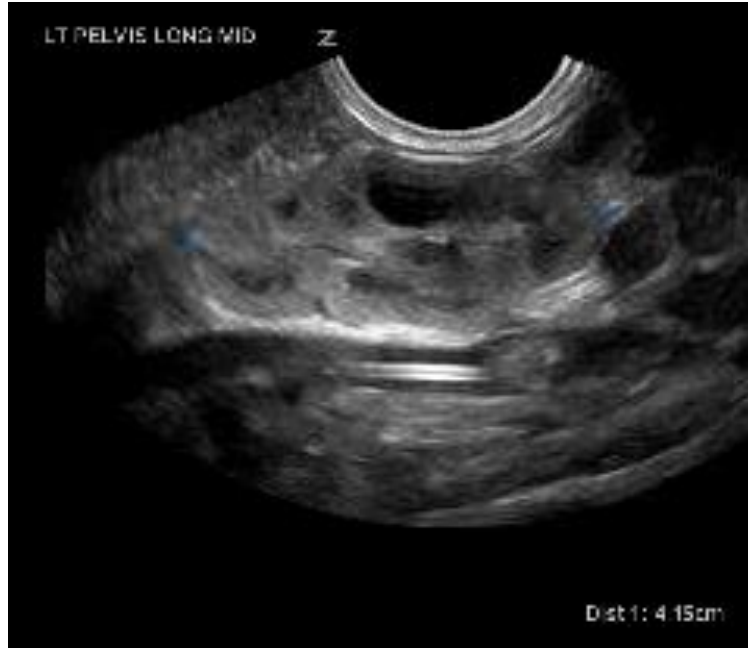Renal ultrasound – DOL #3

Right kidney



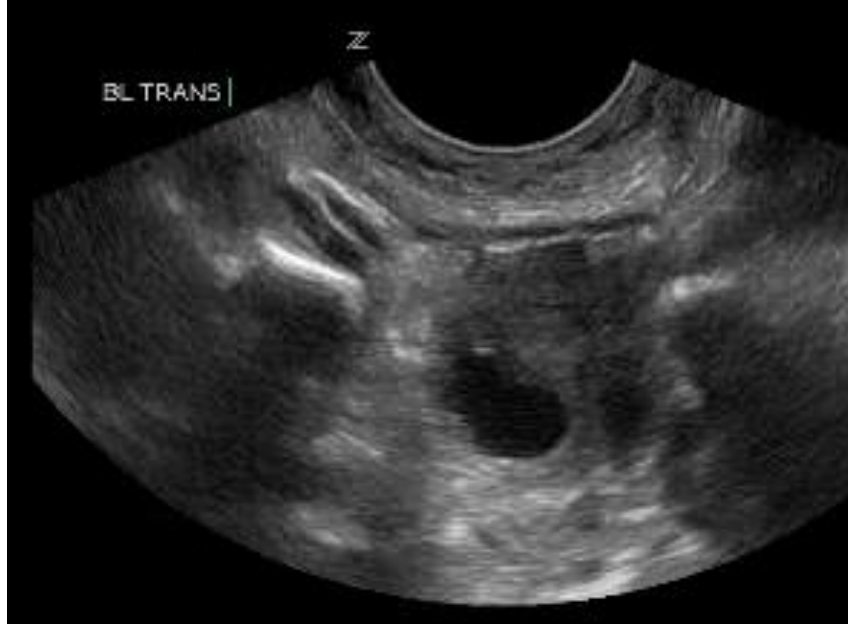Renal ultrasound – DOL #3

Left pelvic kidney

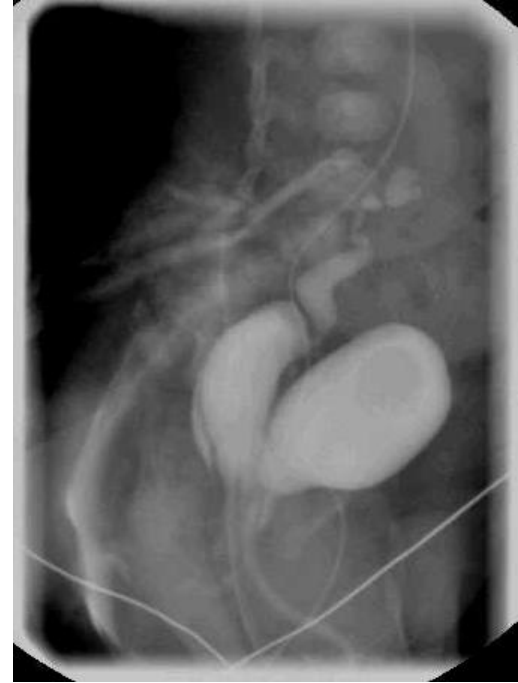
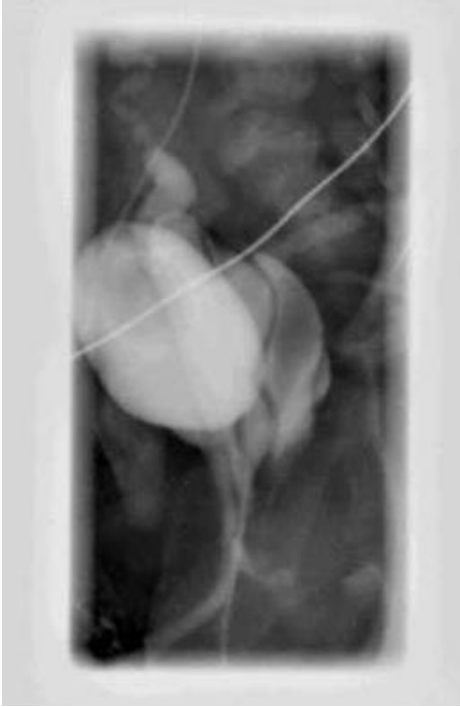
Renal ultrasound – DOL #3

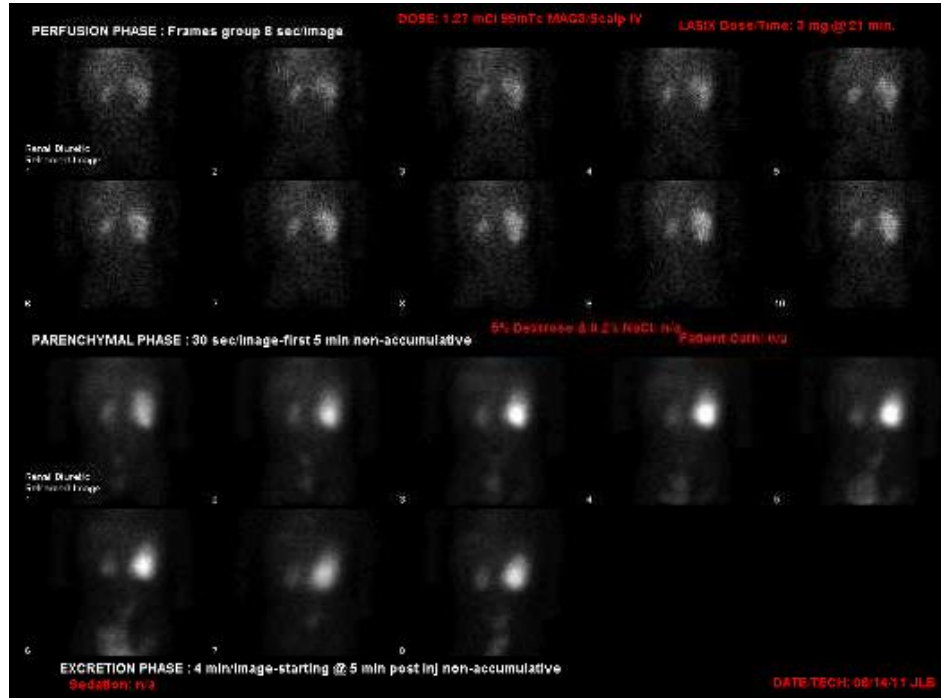
Bladder



VCUG - DOL #11



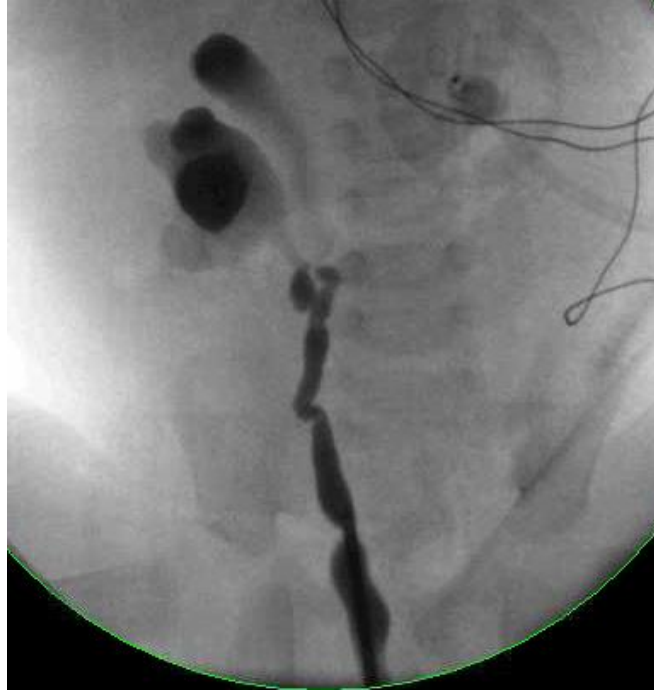MAG3 renogram – 1 month of life



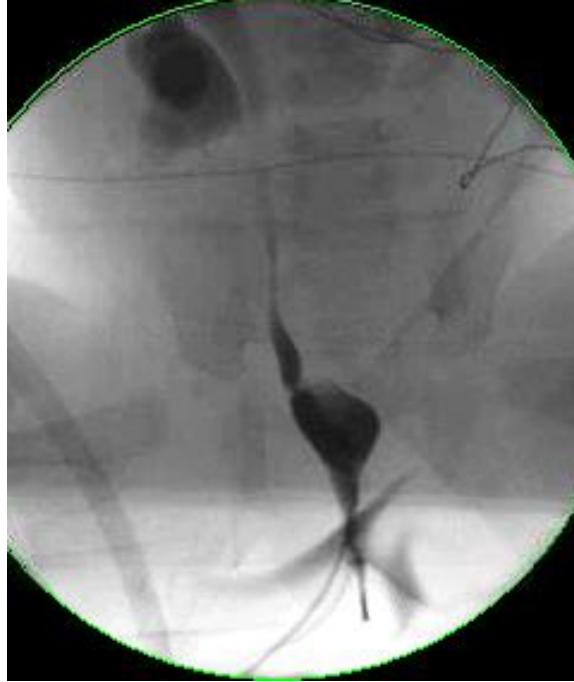EUA – 5 months of age

- Urogenital sinus
- Duplicated vagina
- Gaping ectopic ureteral orifice into the right hemivagina
- Unable to identify the left ureteral orifice
- Extremely small bladder – estimated capacity 10cc

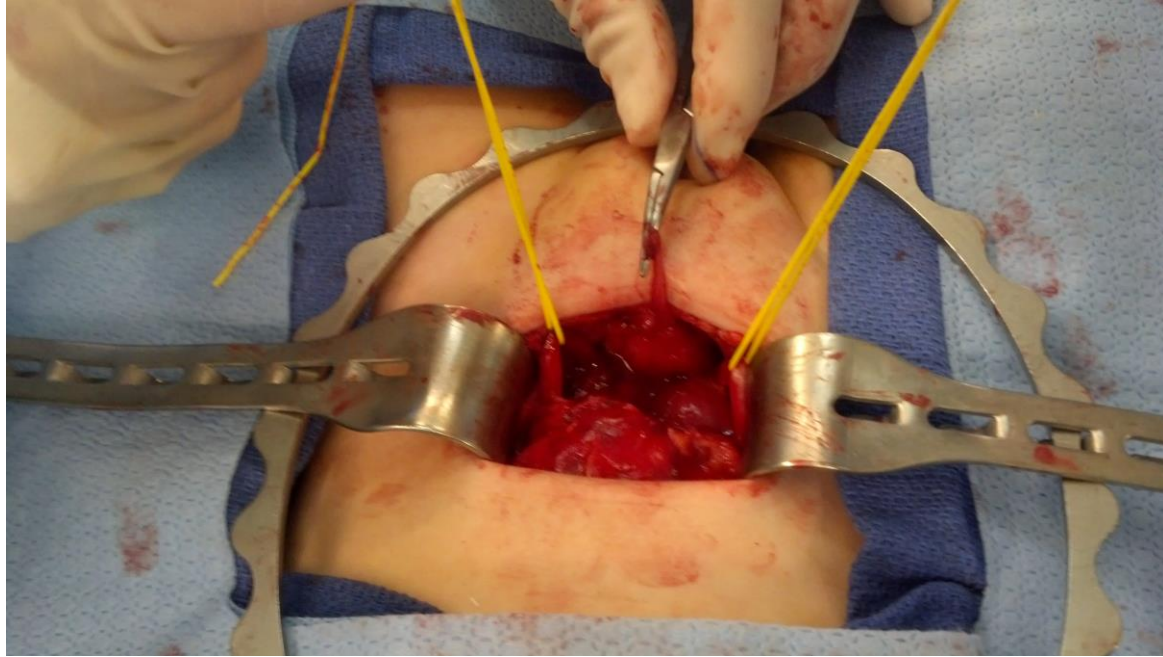
RPG at time of EUA



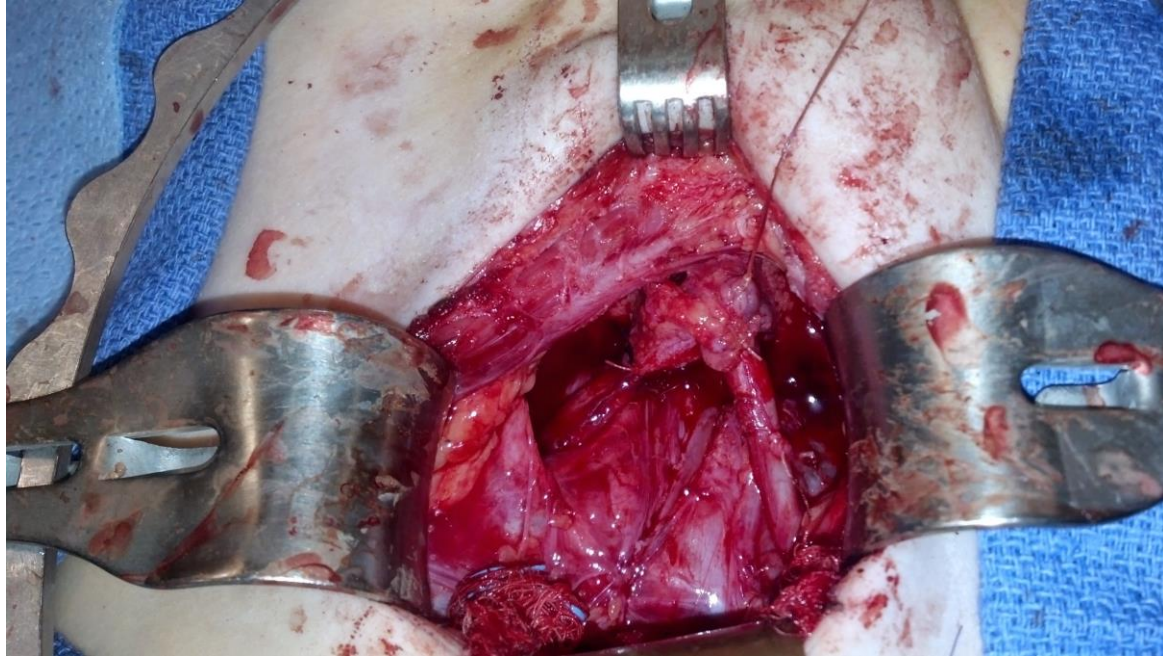
Cystogram at time of EUA



Bilateral ureteral reimplantation – age 26 months

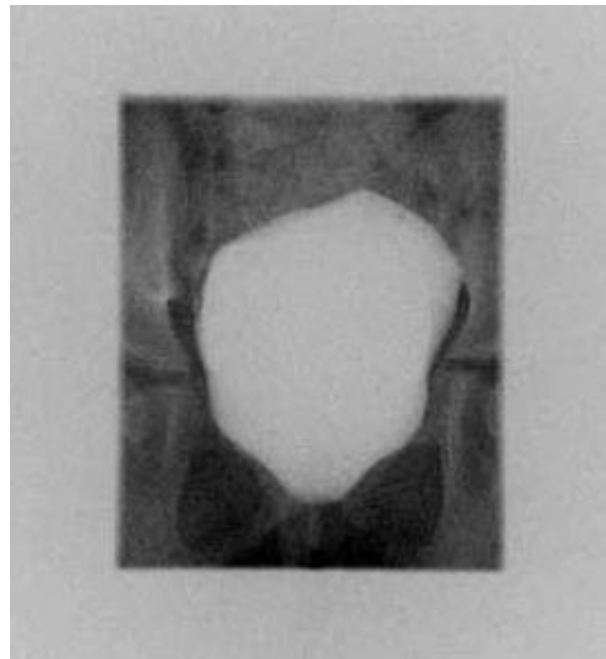


Bilateral ureteral reimplantation – age 26 months



Long term follow-up

- UG sinus repair at age 3
- UDS at age 5
 - Bladder capacity 210mL
- Most recent FU (age 7)
 - Normal voiding patterns
 - **No daytime incontinence**



Takeaway

- Patients w/ bilateral single system ectopic ureters rarely develop normal voiding patterns
- This patient's ureters were ectopic to hemivaginae, **not** the bladder neck
- **Suggests that continence is dependent solely on bladder neck development**