



**Texas Children's
Hospital®**

Baylor
College of
Medicine

PANEL DISCUSSION: WHAT TO DO WHEN THINGS GO WRONG: AN HONEST LOOK AT COMPLICATIONS

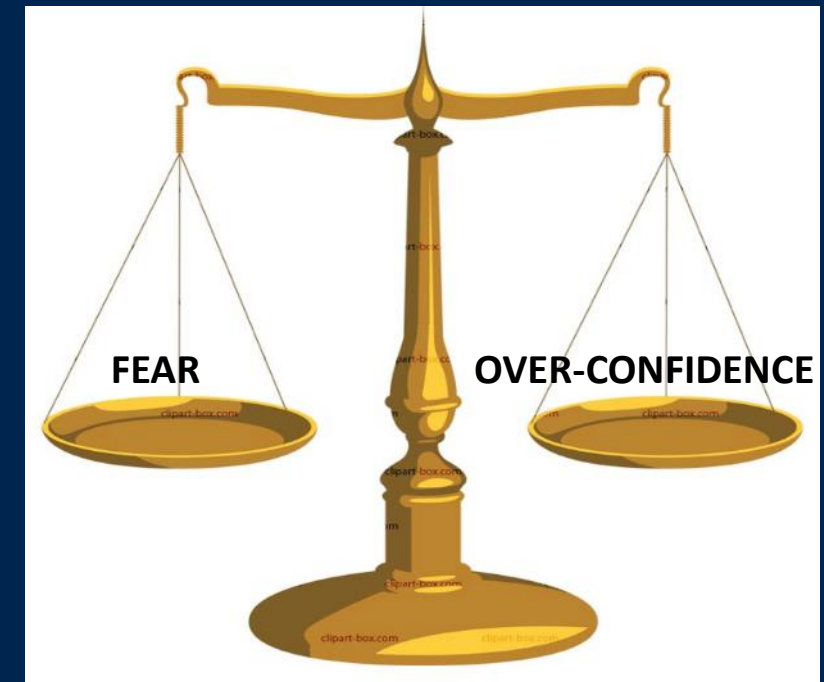Paul F. Austin, MD, FAAP
Professor of Surgery
Division of Urology
Texas Children's Hospital
Baylor College of Medicine

Thank you Dr. Kaefer!




Surgical Complications

- Ultimate Problem-Based Learning
- Self-analysis
 - Classic M&M
 - Error in judgement vs Error in technique
- Requires humility & honesty
- Strive for balance
- Support system
 - Family, colleagues, mentors, counseling



Here's my story...



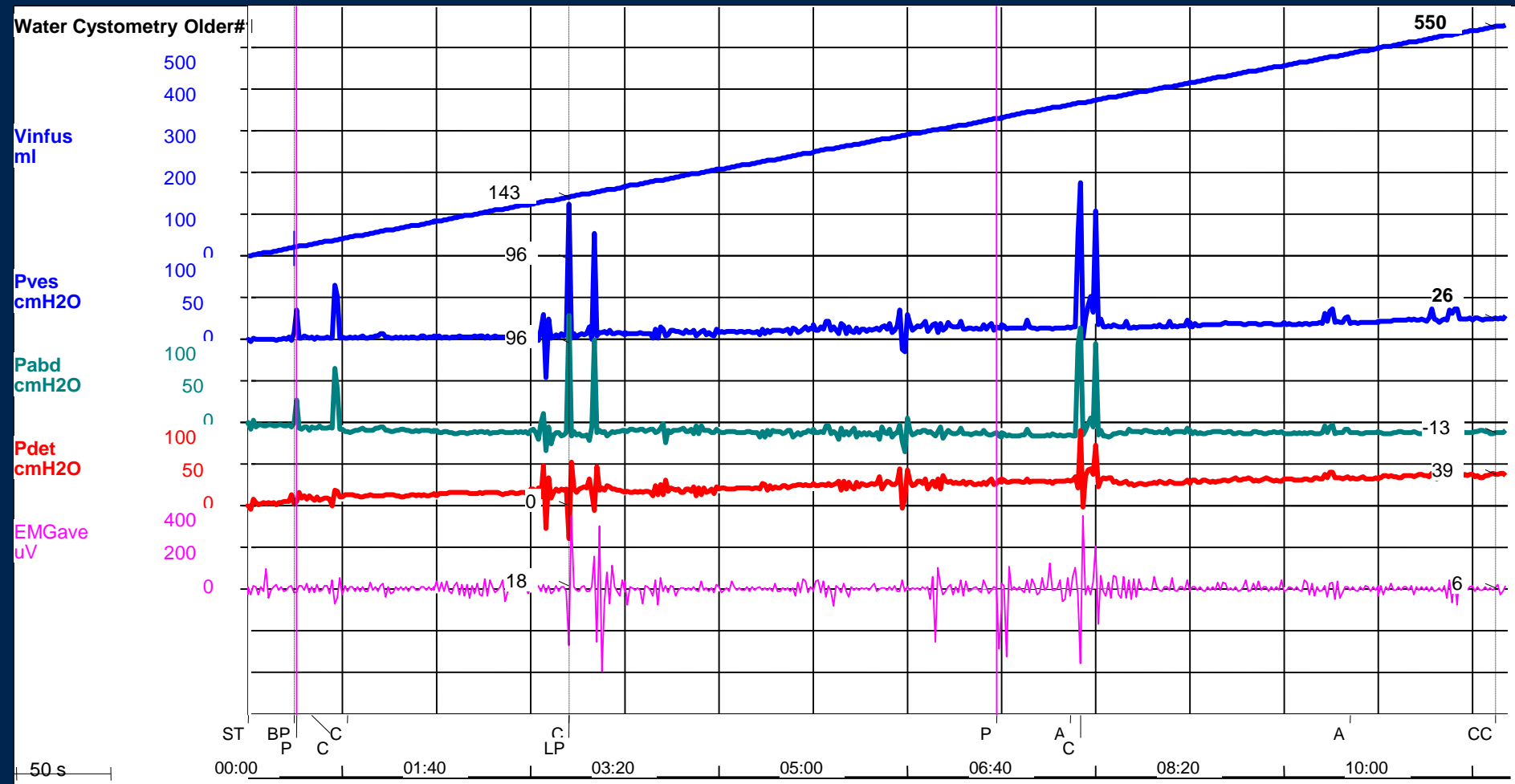
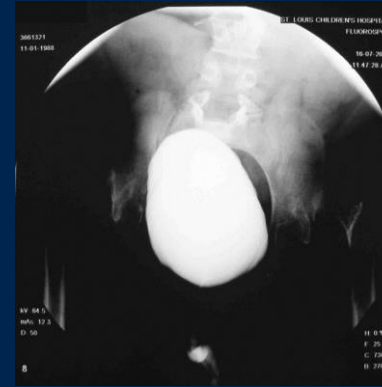
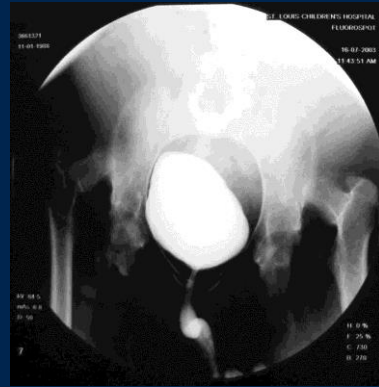Inpatient consultation GS

- 15 y.o. male
- MMC with NGB
- Urinary & Fecal Incontinence
- Chronic sacral decubiti
- 10 years since last seen by GU

Recommendations:

- CIC q 3 hrs
- Anticholinergics
- Schedule VUDS

VUDS



Good bladder compliance

VLPP 96 @ 143 ml

P_{DET} 26 @ 500 ml

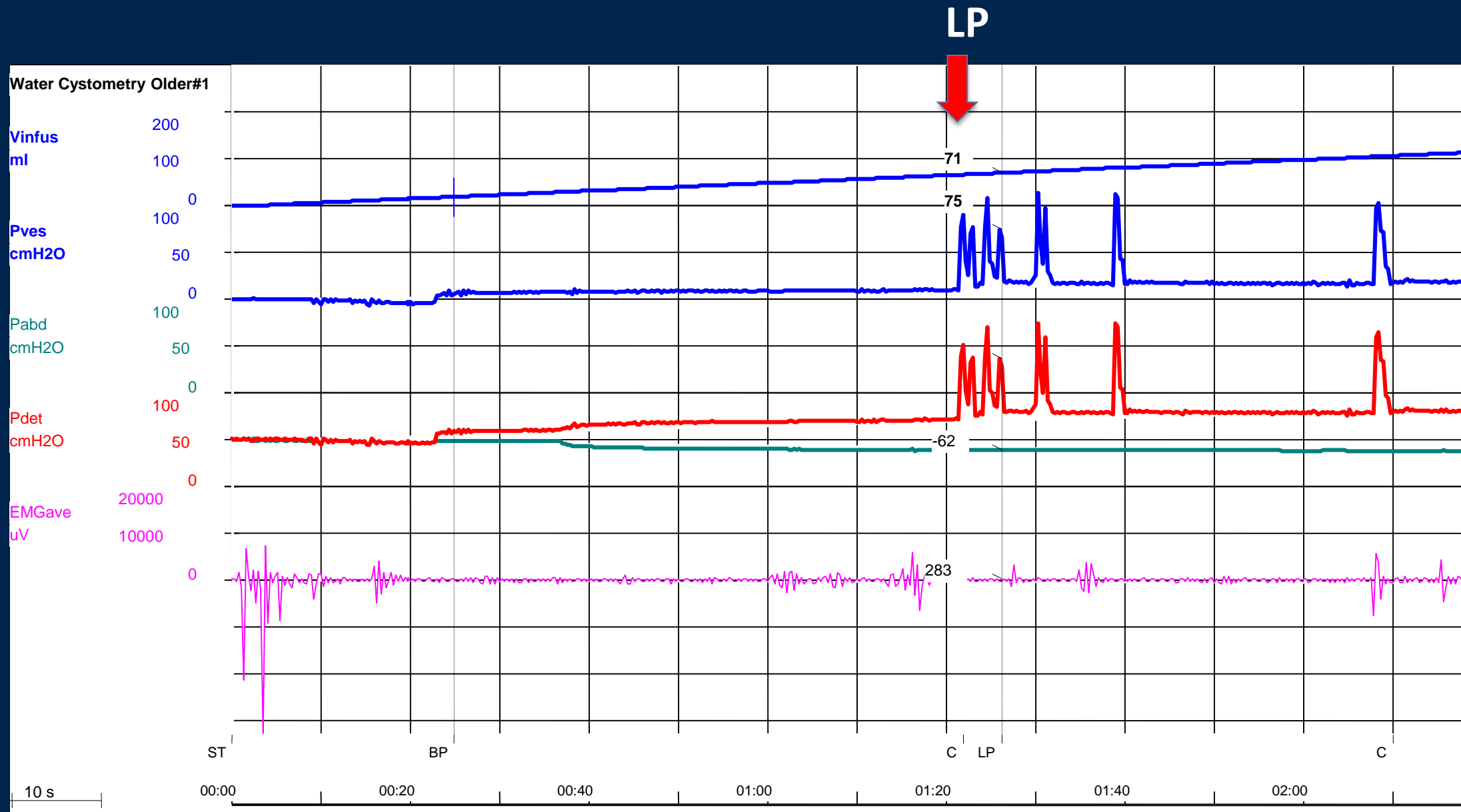
SURGERY

- Bladder neck sling
- Continent ileovesicostomy (Spiral Monti)
- MACE

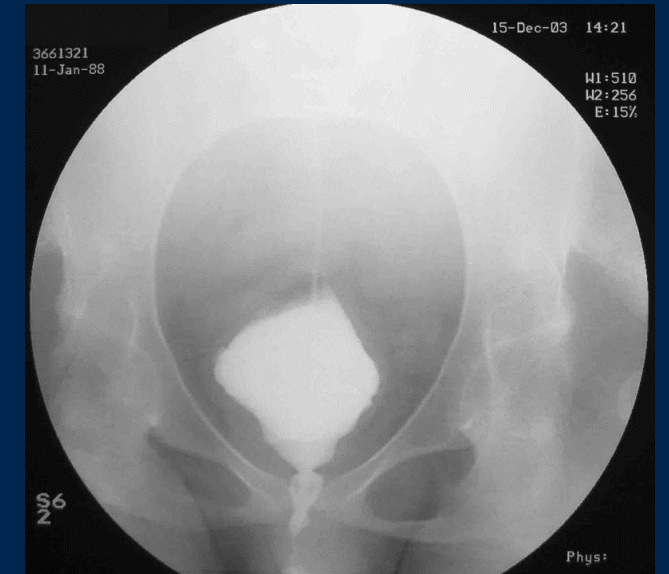FOLLOW-UP

- 4 weeks post-op
 - Removed catheters & began CIC
- 1 mo post-op
 - Leaking between CIC

VIDEOURODYNAMICS

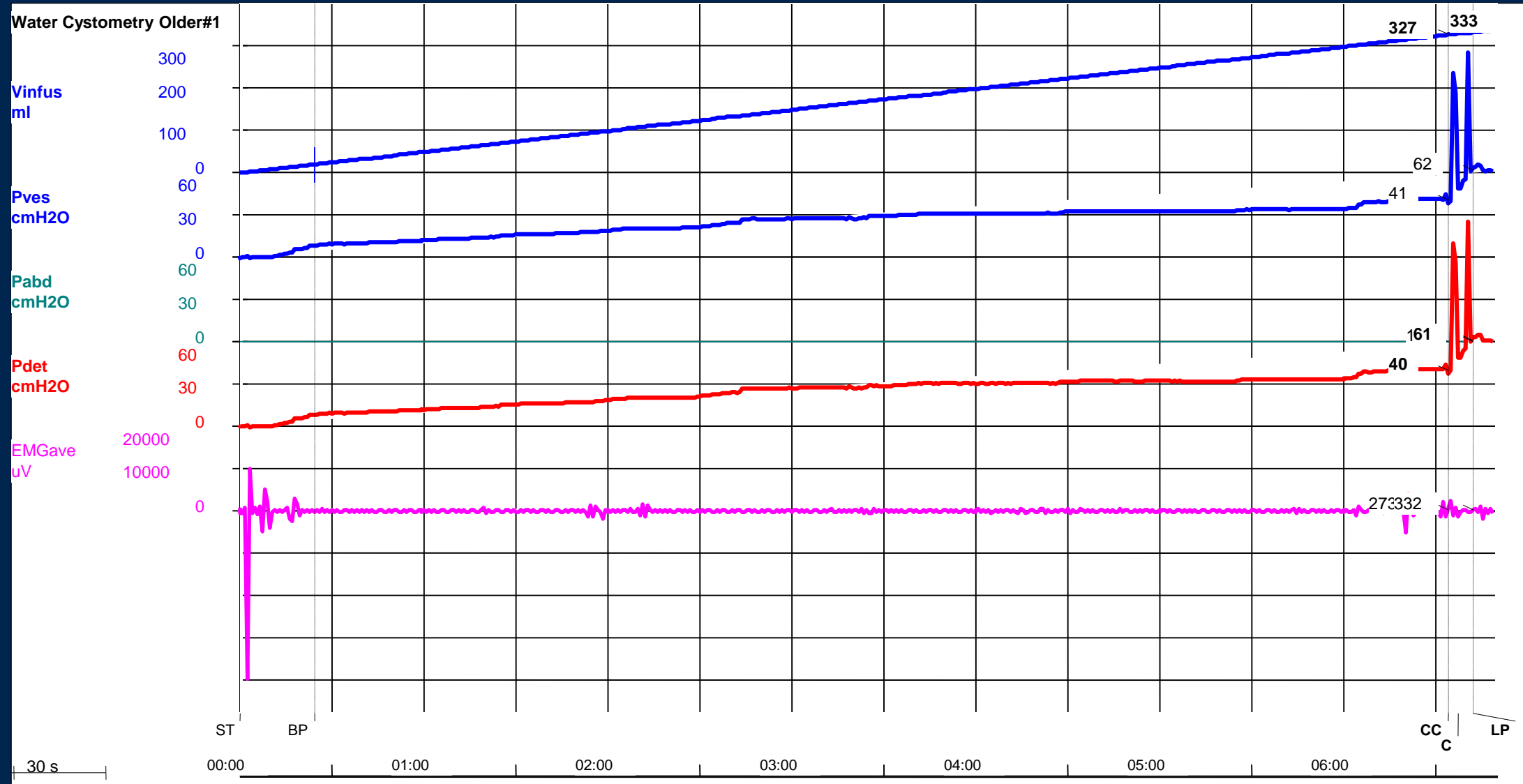


VLPP 75 @ 71 mL



VIDEOURODYNAMICS

Urethra occluded



P_{DET} 40 @ 325 mL
+/- bladder compliance

RECOMMENDATIONS

- BN injection vs. BN closure

• Patient opted for bladder neck closure

- 4 weeks post-op cystogram normal

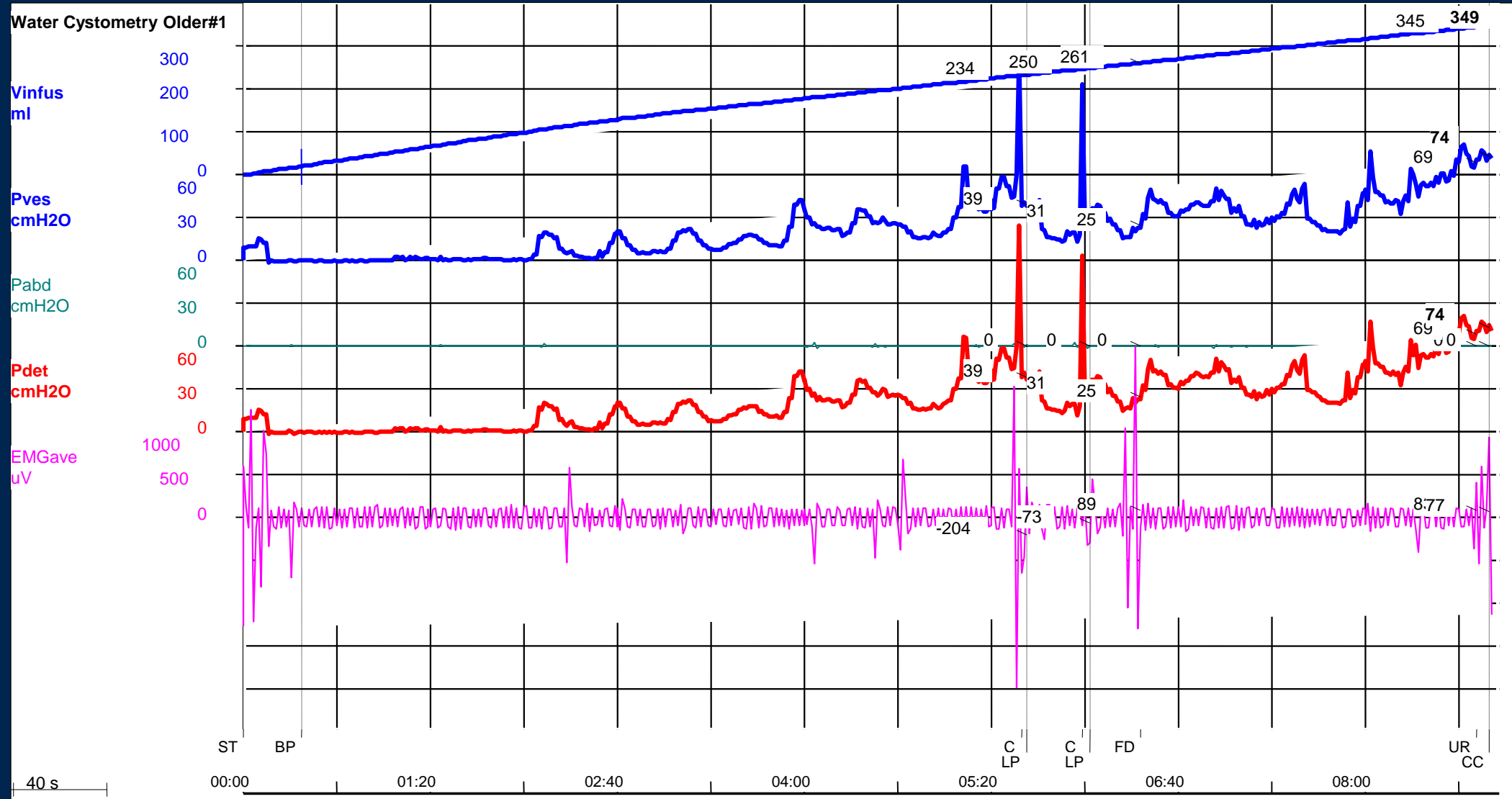
FOLLOW-UP

- **New incontinence!**
 - 3 weeks after negative cystogram
 - 7 weeks after surgery
- **Repeat video UDS**

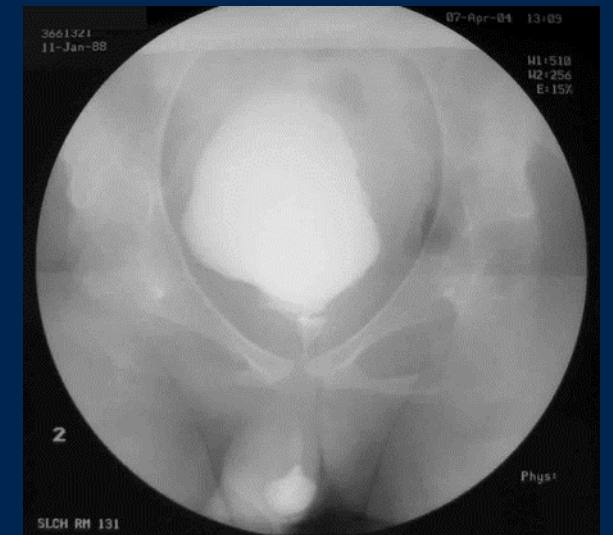


URODYNAMICS

Urethra occluded



Significant NDO
↓ compliance




SURGERY

- Bladder neck closure #2
- Enterocystoplasty



PFA

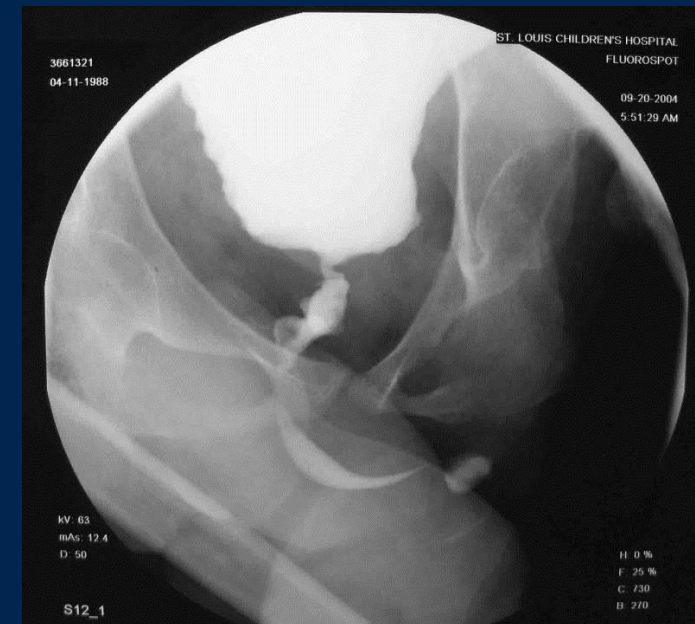
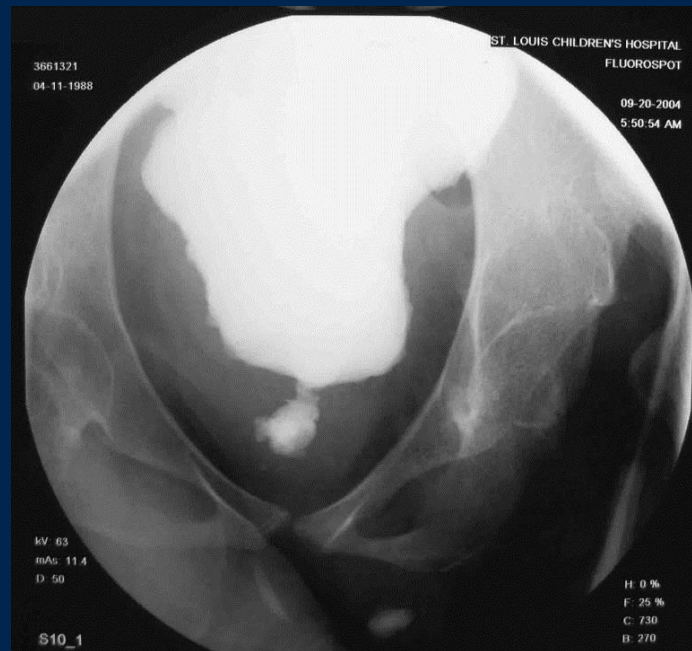
DEC

FOLLOW-UP

- Catheters removed 4 wks post-op
- 1 month later.....

New Incontinence!

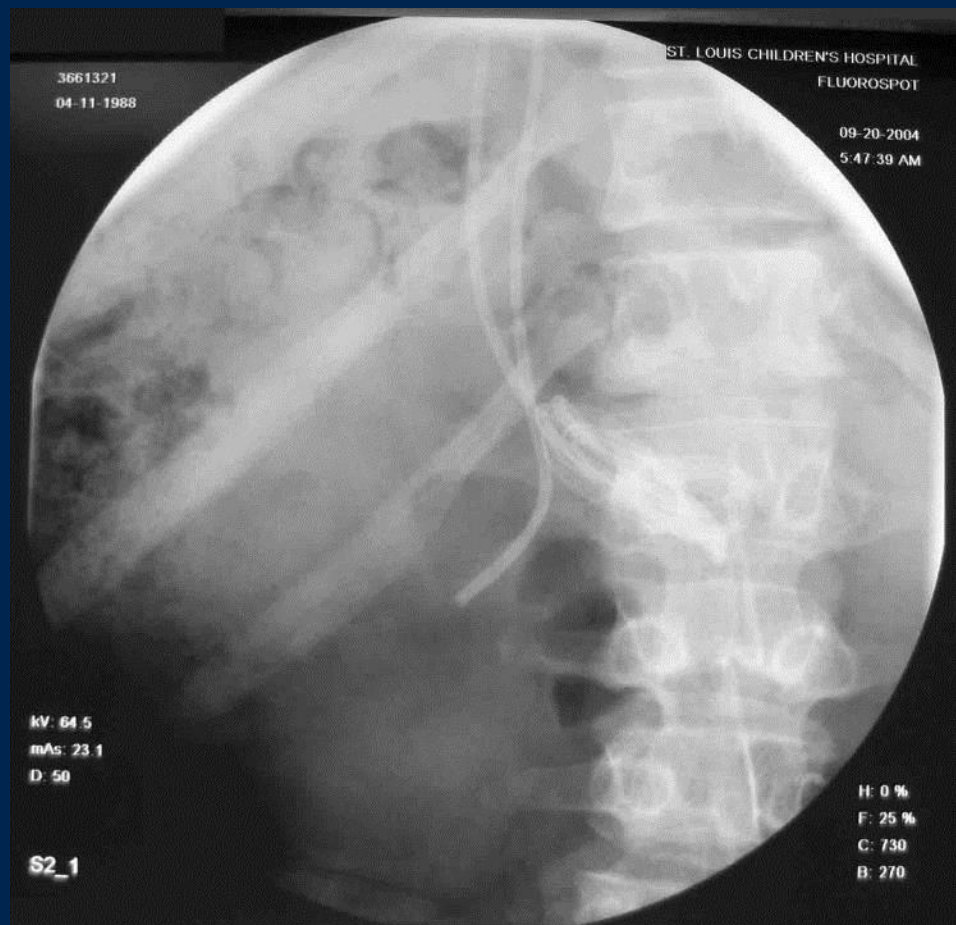

SURGERY

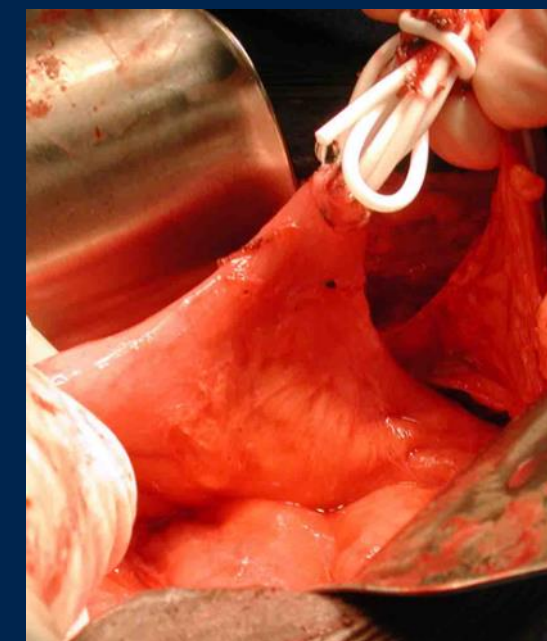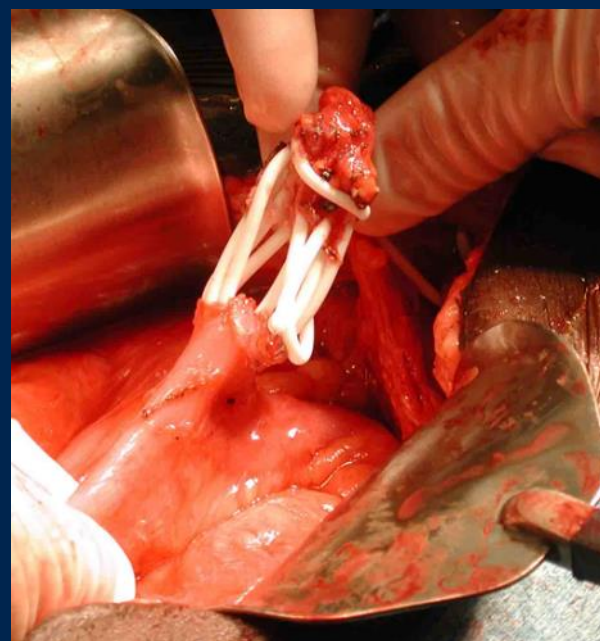
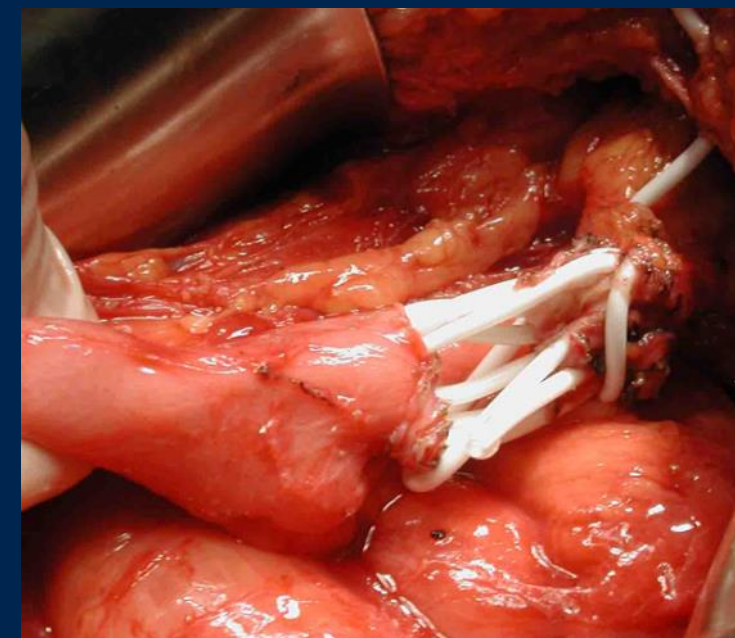
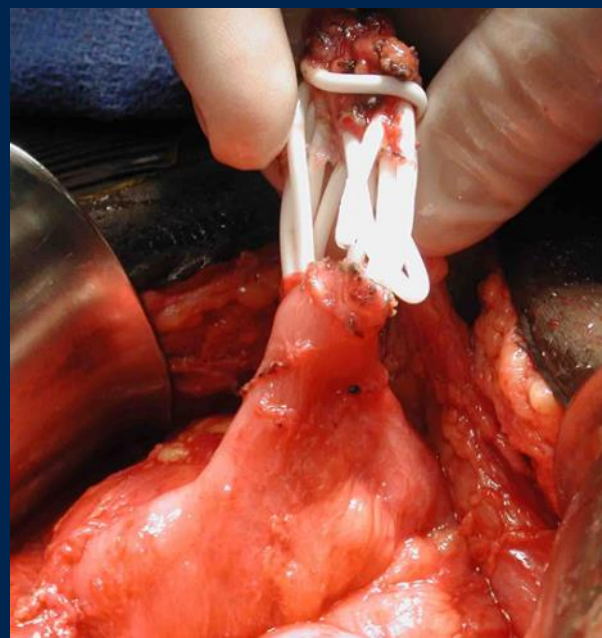
- Bladder neck closure #3
- Enterolysis
- Interposition of omental flap

During the omental
dissection....

VP Shunt

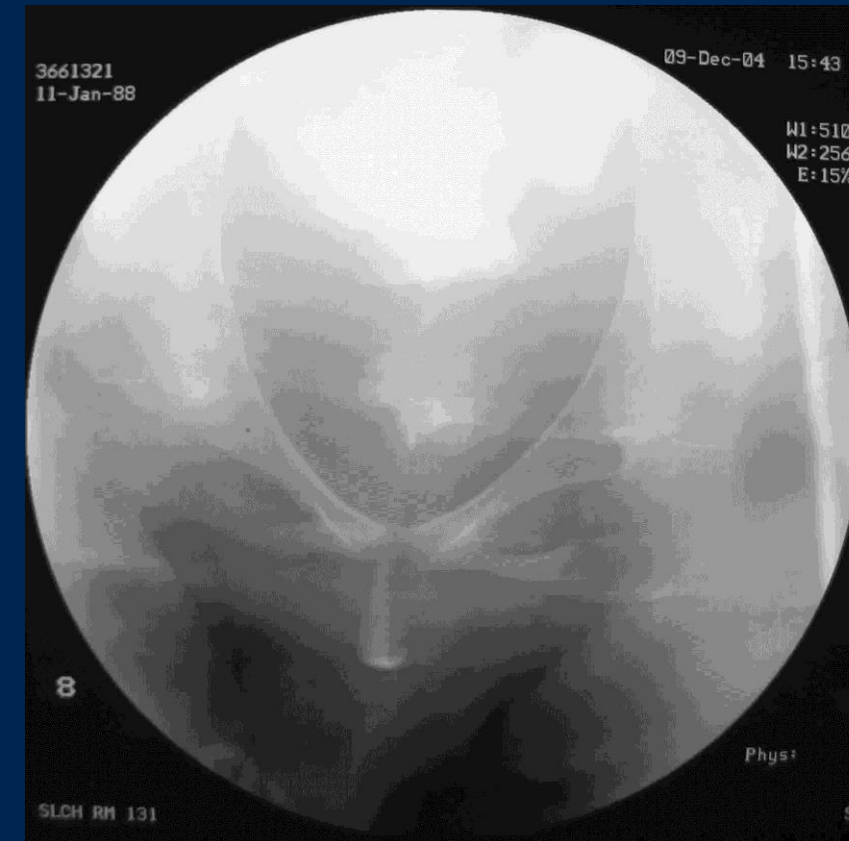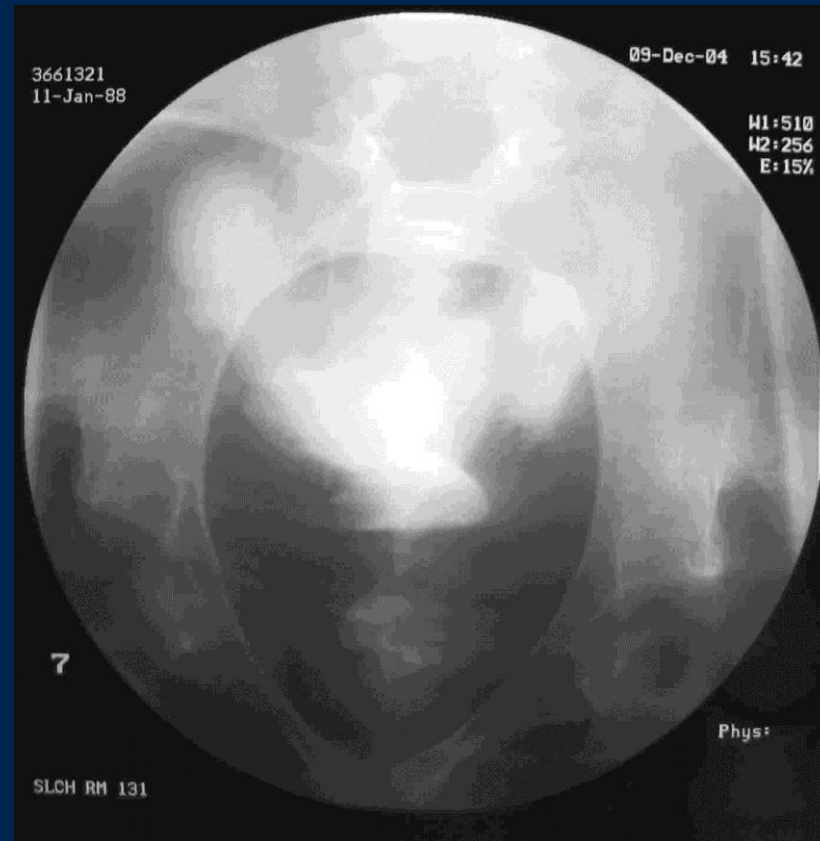


Enterolysis



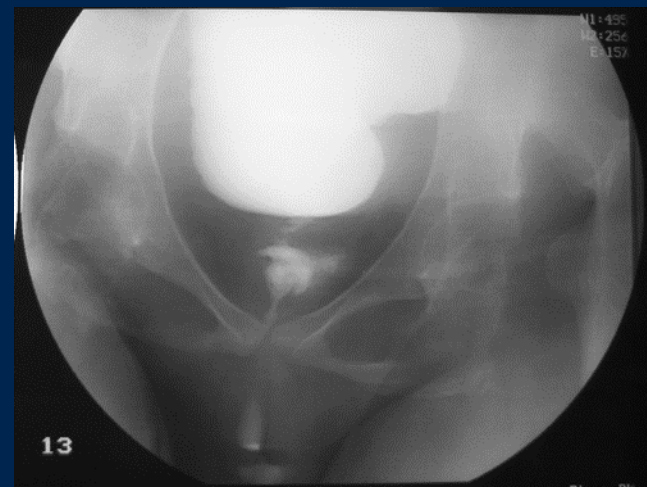
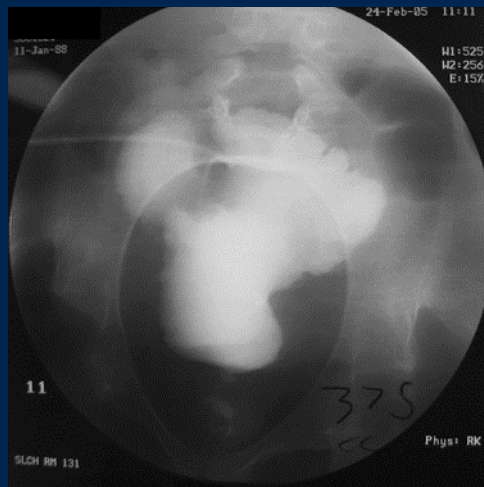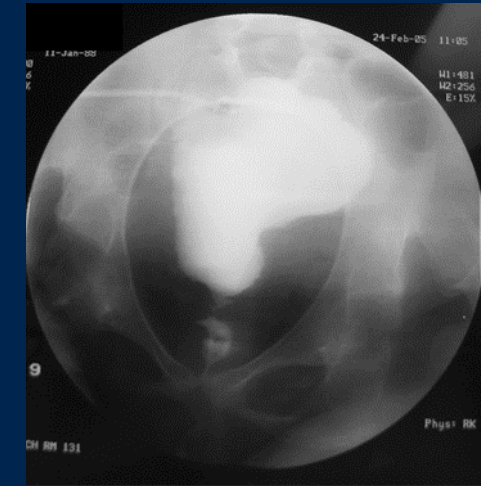
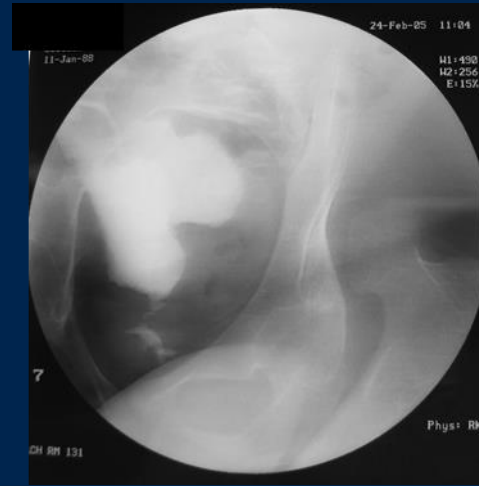
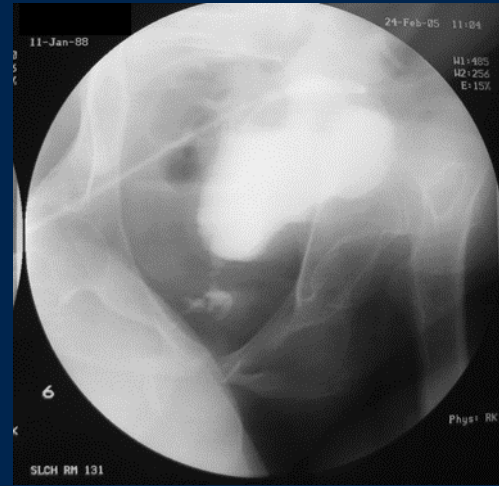
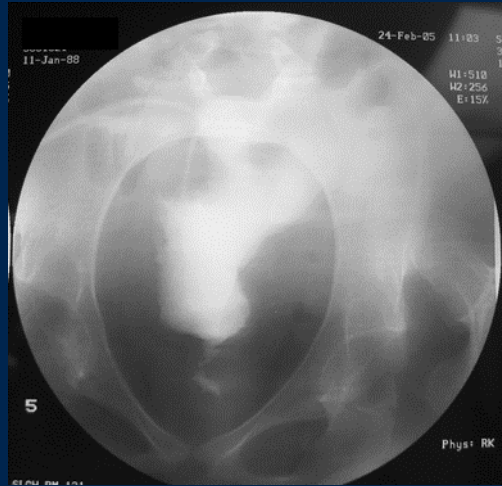
FOLLOW-UP

- Cystogram 1 month post-op



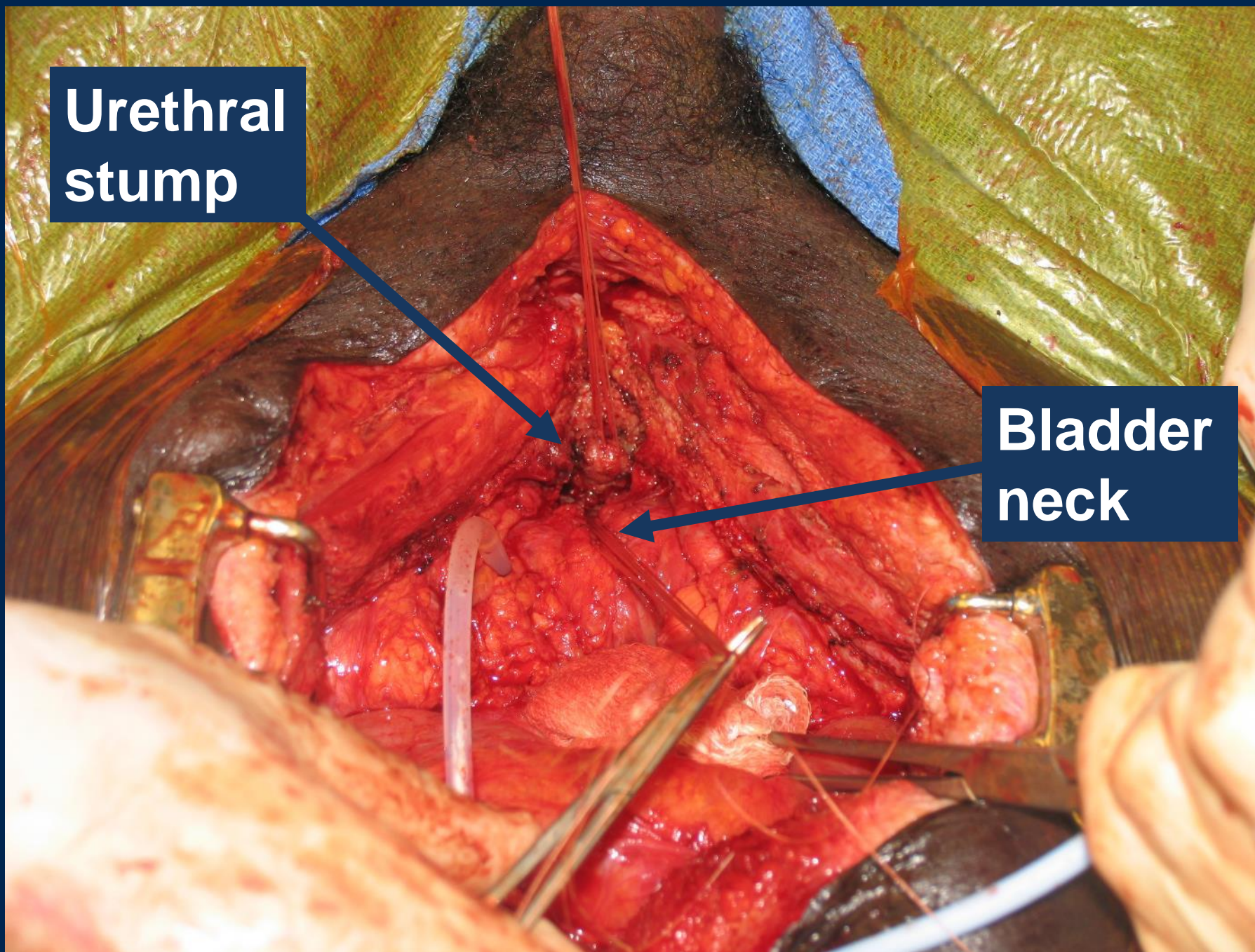
Leakage @ 350 ml

Total 12 wks bladder decompression



• Continues to leak

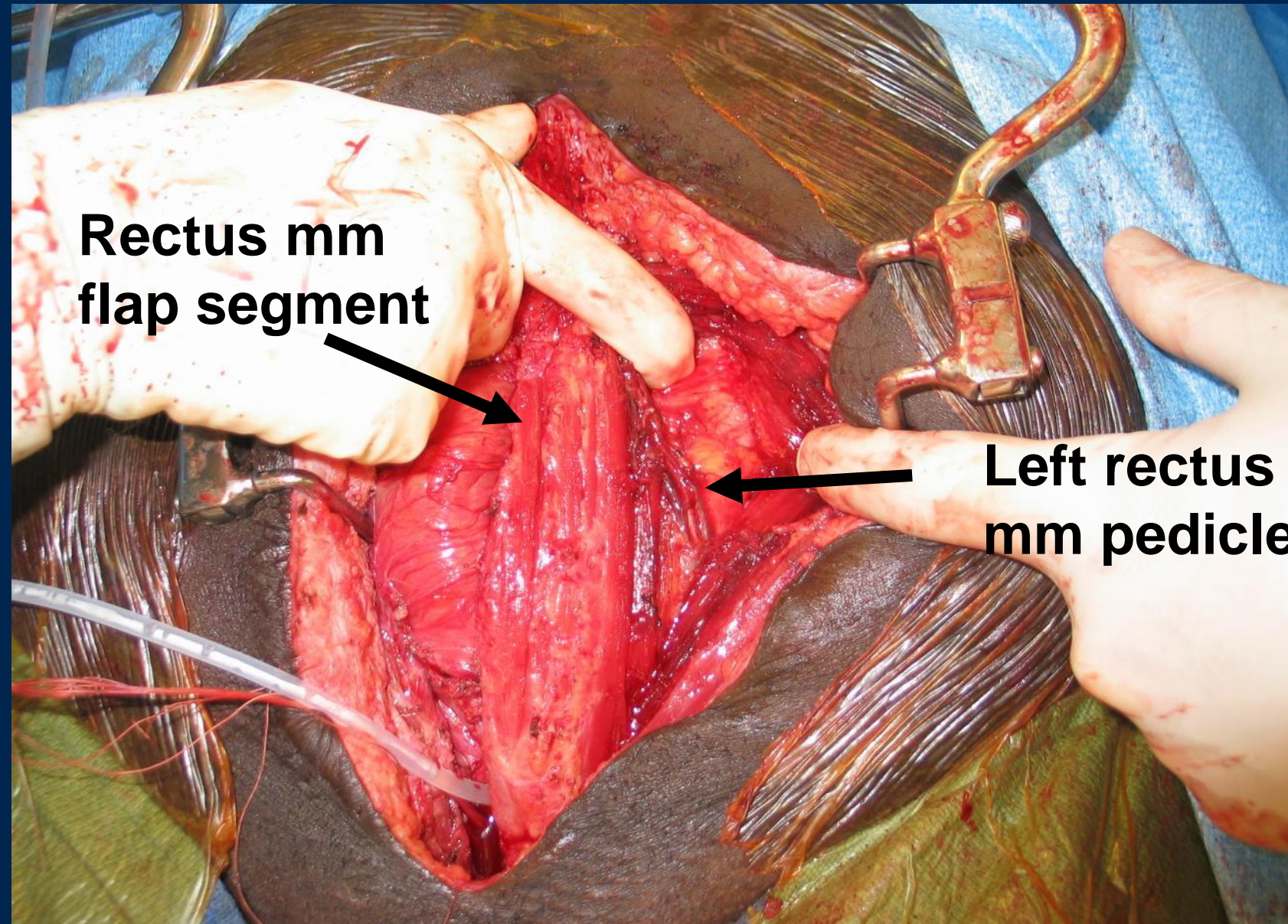
BN CLOSURE #4



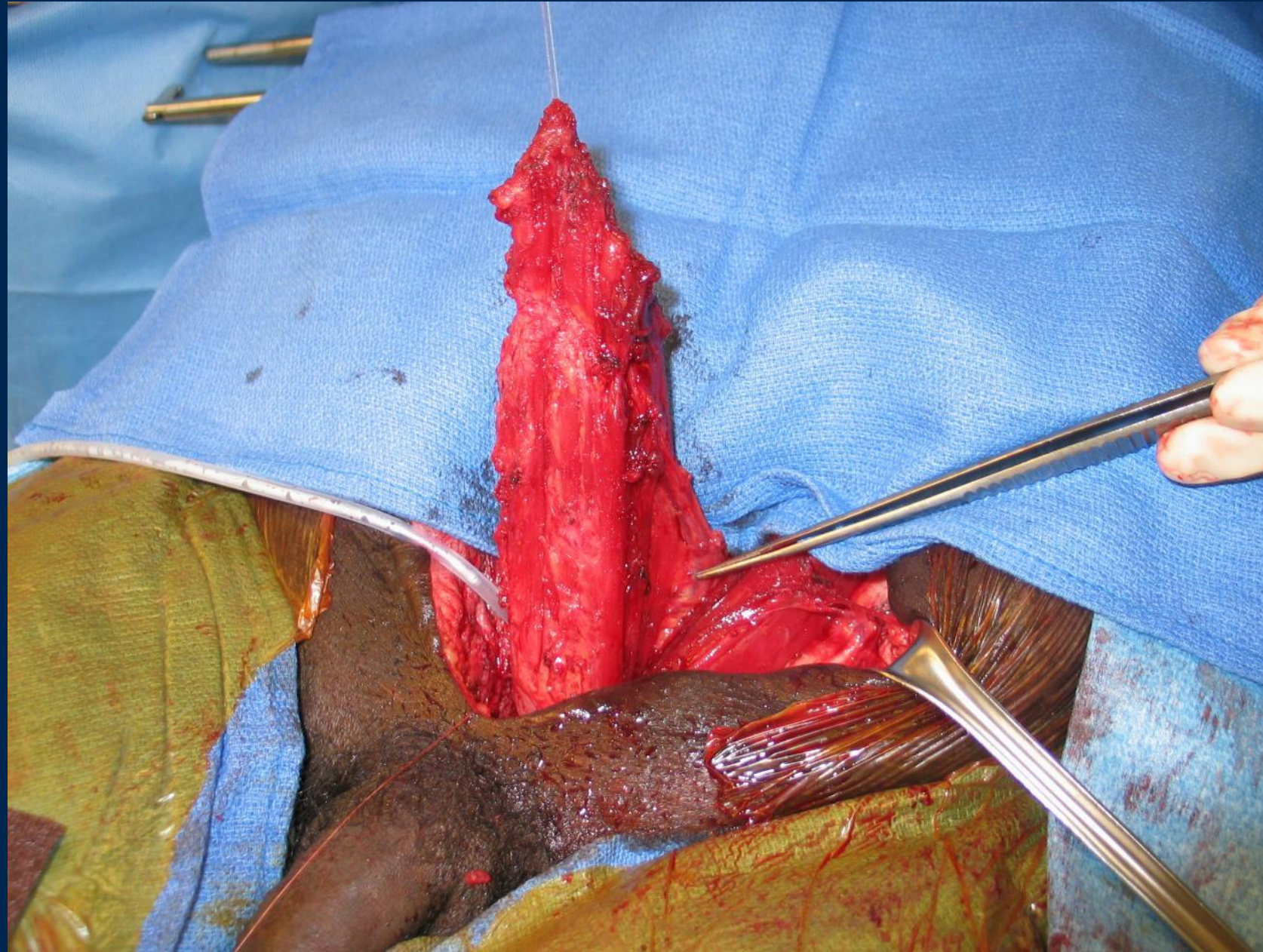
**Urethral
stump**

**Bladder
neck**

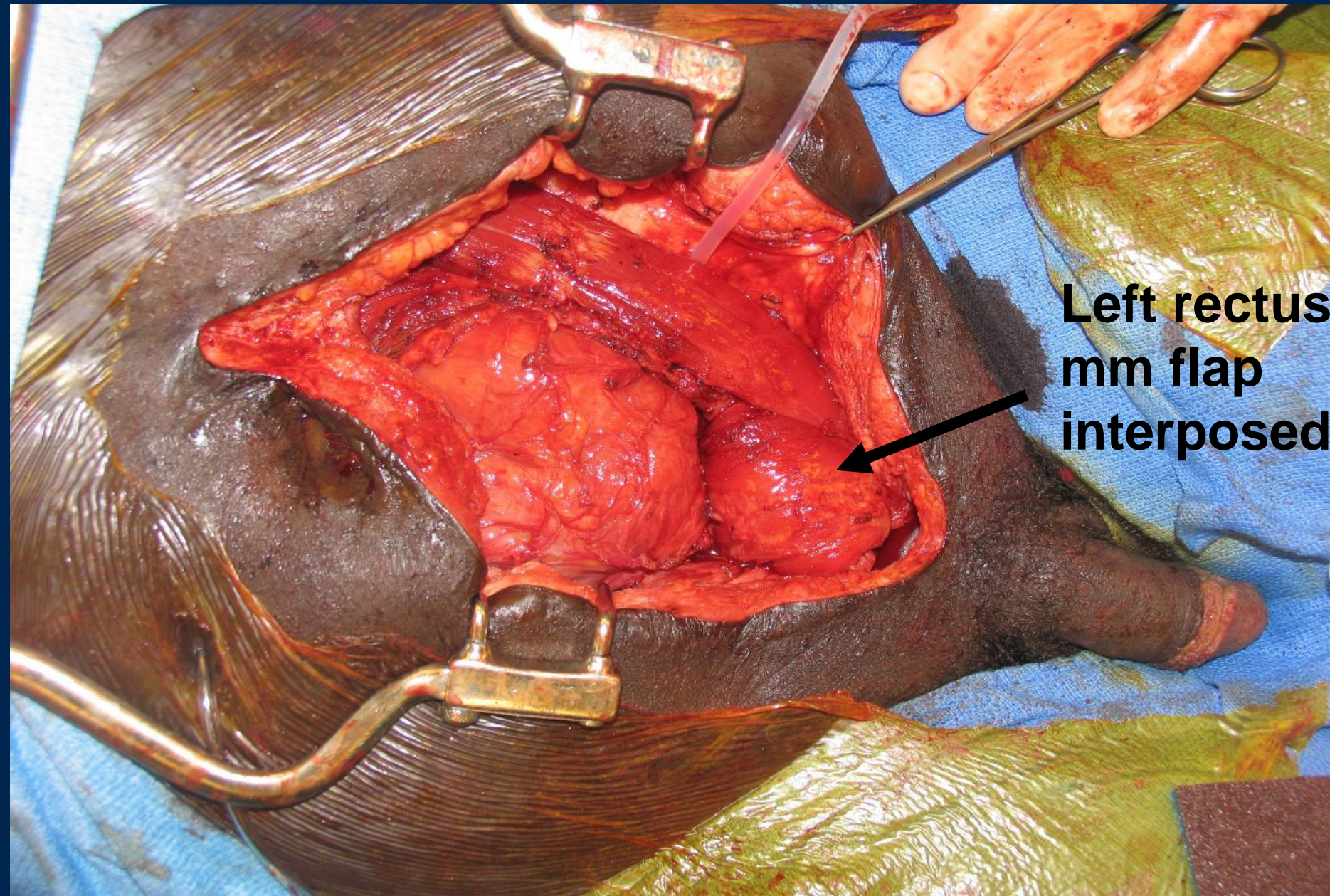
RECTUS MUSCLE HARVEST



RECTUS MUSCLE PEDICLE



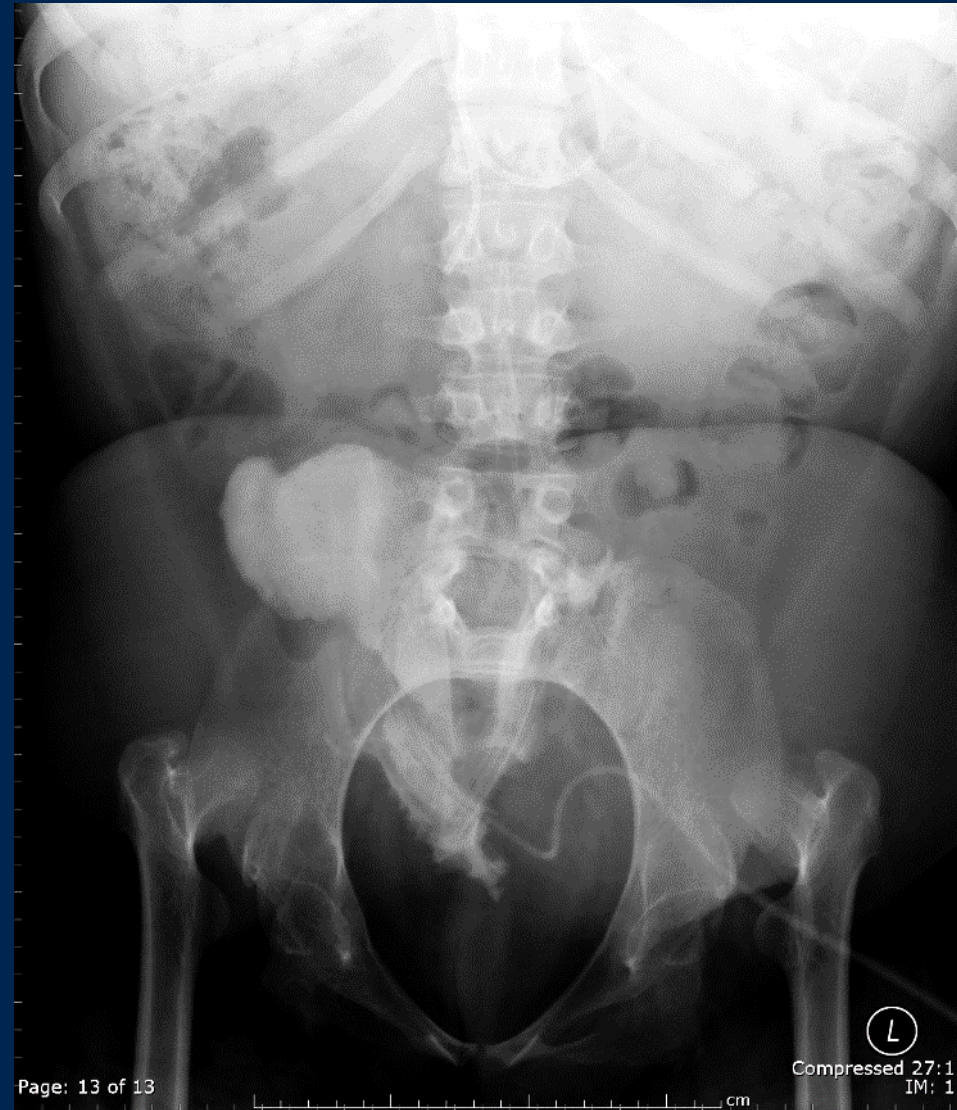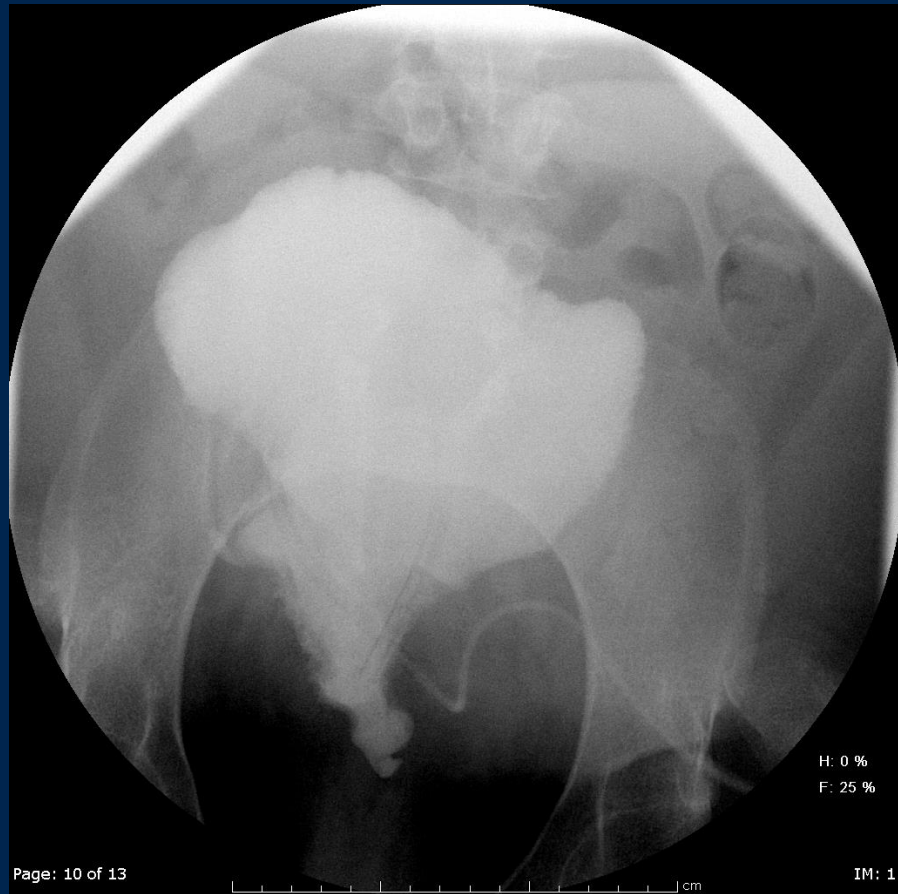
RECTUS MUSCLE INTERPOSITION




**Left rectus
mm flap
interposed**

POST-OP CYSTOGRAM

- No leakage!



THE END



"Lord, we thank thee."