



Neonatal Testicular Torsion: Argument for Emergent Management

Glenn Cannon, MD
Division Chief, Pediatric Urology
Associate Professor of Urology
University of Pittsburgh School of Medicine

The Nightmare Scenario

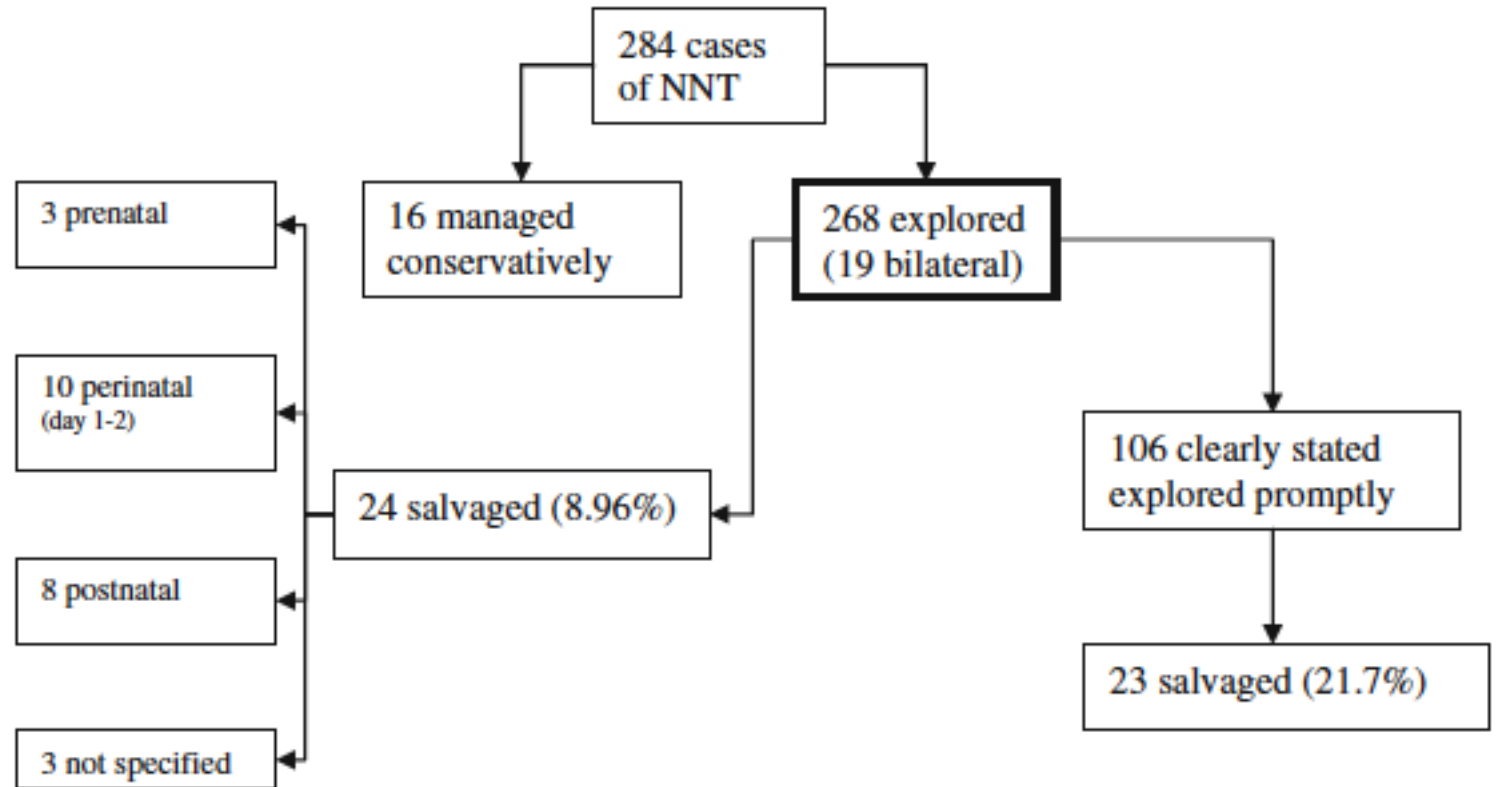
- As the urologist on call, in the middle of the night, you receive word of a newborn with a edematous, ecchymotic hemi-scrotum. Ultrasound reveals no flow.
- You elect not to emergently transfer and explore.
- The newborn develops contralateral edema/ecchymosis.
- Exploration reveals bilateral necrotic testes. The child is anorchid for life.
- You are sued for failure to diagnose/treat.
- After a lengthy legal process that takes a great deal of your time and causes you a great amount of stress, you lose the case and the jury gives a massive award to the plaintiff's parents.
- The award exceeds your insurance coverage and you end up losing everything that you hold dear.

Framing The Argument

- Basic Facts
 - Incidence
 - Asynchronous events
- Anesthesia Risks
 - Specific risks in neonates
 - Regional anesthesia
- Medicolegal Consequences
 - Length of litigation
 - Jury awards

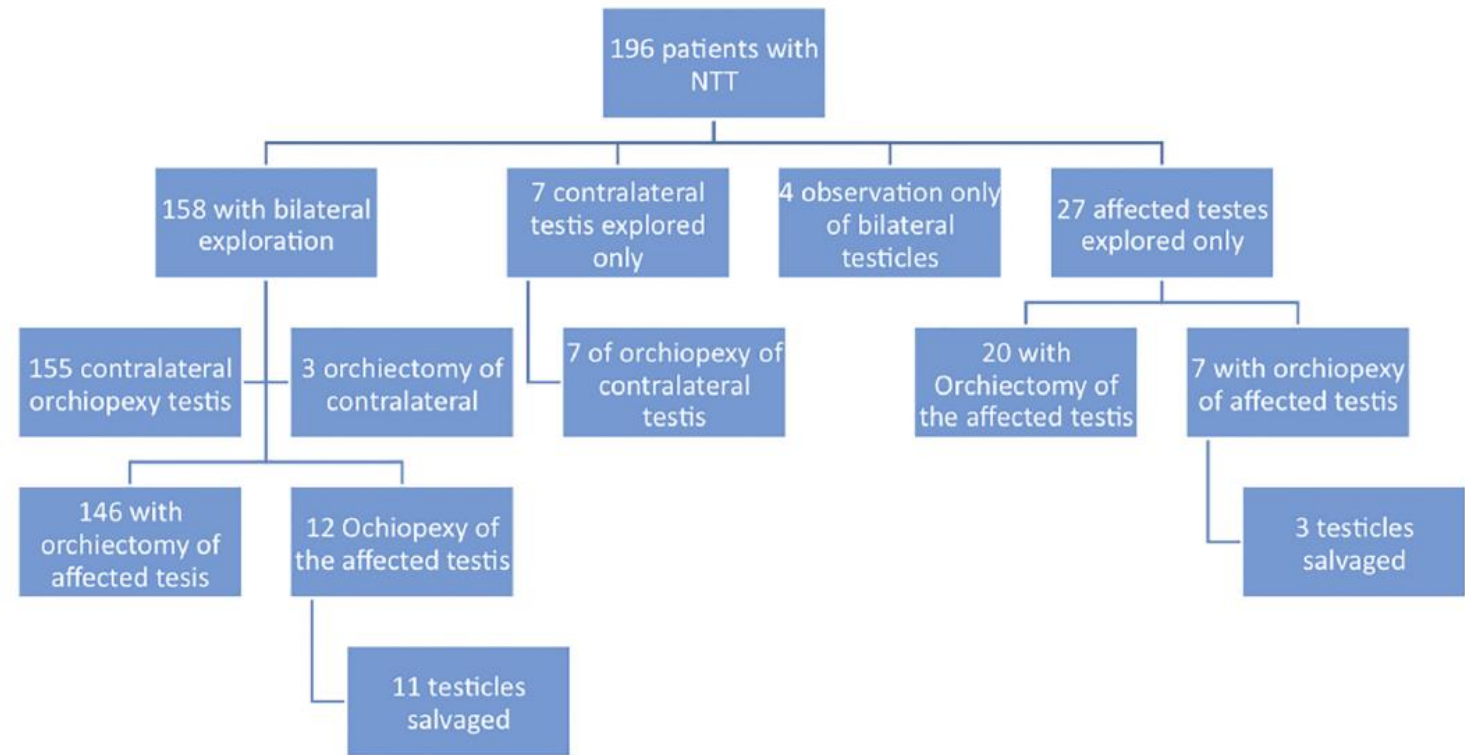
Neonatal Testicular Torsion (NTT): 2011 Literature Review

- Incidence 6.1:100,000
- Bilateral risk: 8%
- Only 1 asynchronous
- 5% Intravaginal



2019 Literature Review

- 7% Bilateral
- 4% Asynchronous
- Overall salvage 7%



Literature Summary

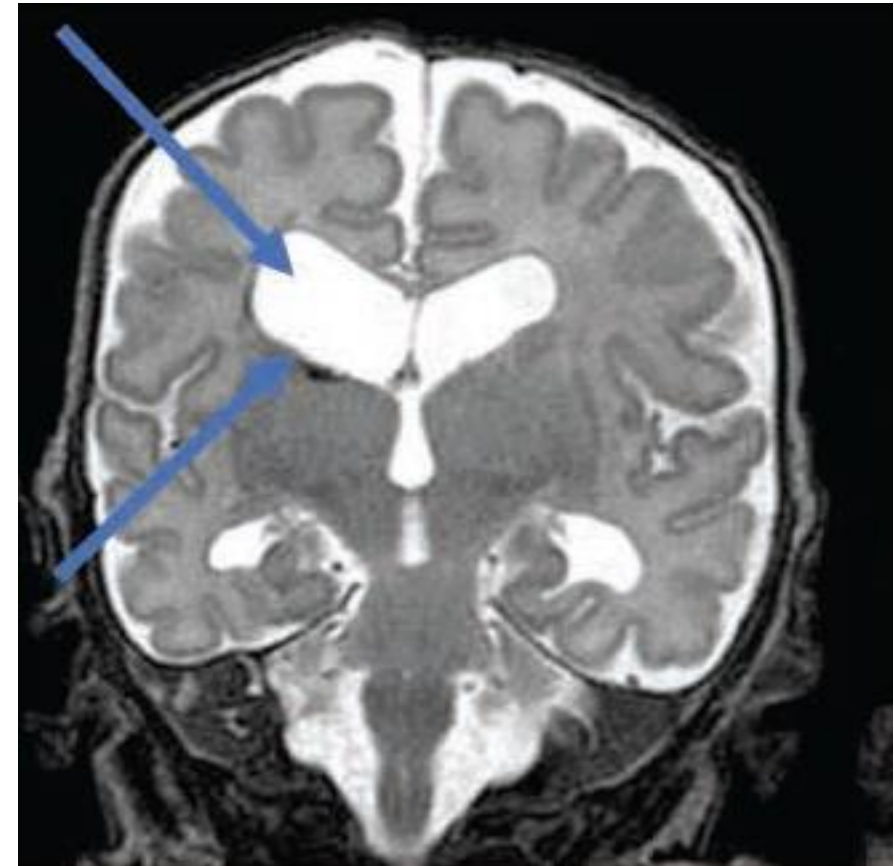
- Asynchronous torsion risk is real (but rare)
 - Reported in multiple literature reviews and case reports
 - It has been reported to occur anywhere from hours after birth to 6 months of age
 - Many in the audience have personally seen it
- Torsion is not always extravaginal
- Salvage has been reported (but rare)
- Ultrasound is not 100% sensitive nor specific
 - Contralateral torsion has been reported with normal ultrasound

Bandi P, Murphy FL. Neonatal Testicular Torsion: A Systemic Literature Review. *Pediatr Surg Int* (2011) 27:1037–1040

Monteilh C, Caxilte R, Burjonrappa S. Controversies in the Management of Neonatal Testicular Torsion: A Meta-Analysis. *Journal of Pediatric Surgery* 54 (2019) 815–819

Anesthesia Risks in the Newborn

- Infants who undergo surgical procedures in the first few months of life are at higher risk
 - Death
 - Neurodevelopmental abnormalities
- Altered cerebral perfusion
- Metabolic cellular insufficiency
- Production of neurotoxic mediators



McCann ME, Lee JK, Inder T. Beyond Anesthesia Toxicity: Anesthetic Considerations to Lessen the Risk of Neonatal Neurological Injury. *Anesthesia & Analgesia* 2019 (in press).

What about the GAS Study?

- From 2007-2013, 722 infants undergoing inguinal hernia repair randomized to receive general or awake-regional anesthesia
- Finding: no difference in neurodevelopment outcome at 5-years of age
- Caveats
 - Median duration of anesthesia time was 54 minutes
 - Mean age at surgery about 70 days

McCann ME, de Graaff JC, Dorris L, Disma N, Withington D, Bell G, Grobler A, Stargatt R, Hunt RW, Sheppard SJ, Marmor J, Giribaldi G, Bellinger DC, Hartmann PL, Hardy P, Frawley G, Izzo F, von Ungern Sternberg BS, Lynn A, Wilton N, Mueller M, Polaner DM, Absalom AR, Szmuk P, Morton N, Berde C, Soriano S, Davidson AJ; GAS Consortium. Neurodevelopmental outcome at 5 years of age after general anaesthesia or awake-regional anaesthesia in infancy (GAS): an international, multicentre, randomised, controlled equivalence trial. *Lancet*. 2019 Feb 16;393(10172):664-677. doi: 10.1016/S0140-6736(18)32485-1. Epub 2019 Feb 14. Erratum in: *Lancet*. 2019 Aug 24;394(10199):638.

Awake-Regional Anesthesia

- Spinal anesthesia has been increasingly utilized in a variety of urological procedures
- Neonatal testicular torsion has been successfully managed with caudal/local anesthesia
- As these techniques become more widely available, the argument to not treat NTT as an emergent condition due to general anesthesia risks will weaken

Ebert KM, Jayanthi VR, Alpert SA, Ching CB, DaJusta DJ, Fuchs ME, McLeod DJ, Whitaker EE.
Benefits of spinal anesthesia for urologic surgery in the youngest of patients. *Journal of Pediatric Urology* (2019) 15, 49.e1e49.e5

Medicolegal Consequences: 30 Year Case Review

- Average time between initial presentation and verdict is 5 years
- False-negative ultrasounds present in 64%
- Providers whose patients presented to the ED were less likely to have a successful defense

Terry v. Hicks; 2014 AL Jury Verdicts Rptr.

- Day of life 1 noted to have a “swollen/red” scrotum
- Discharged on day of life 2
- Saw pediatrician on day of life 4: “No concern” but recommended Urology evaluation
- Evaluated by a urologist on day of life 15 due to continued scrotal swelling: ultrasound recommended
 - Not actually obtained until 30 days of age
- Findings: bilateral testicular torsion
- Underwent bilateral orchiectomy
- Successful defense verdict for the urologist
 - Argument that the testes were already dead when the urologist was consulted

**JACOB LYKENS A MINOR BY AND THROUGH HIS PNG TREVOR AND BRANDAN
LYKENS vs. DAVID
LAWRENCE M.D. AND LANCASTER RADIOLOGY Associates; 2015 Medical Litig. Alert**

- Right testicular “bruising/swelling” noted at birth
- Ultrasound performed on DOL 1: bilateral hydroceles with no evidence of torsion
- DOL 3 Pediatrician exam revealed hard, non-transilluminating hemiscrotum, sent to ED
- Ultrasound: right testicular torsion. Emergent exploration, orchiectomy performed.
- Defense verdict returned based on the negative ultrasound

How Much is a Testicle Worth?

- Doe vs. Doe; 2010 UT Jury Verdicts & Sett. Award: \$50,000 (3.5 year old)
- Aaron Krekorian v. Stuart Campbell and the Sutter Auburn Faith Hospital; 2006 Jury Verdicts Award: \$150,000 (16-year old)
- 1992 NJ Jury Verdicts Review Award: \$250,000 (16-year old)
- ORANDAY, FRANCISCO AND MARIA v. DEFENDANT; 1999 Jury Verdicts. Award: \$261,000 (infant)
- Name of case: Withheld; 2005 Dolan Media Jury Verdicts. Award: \$800,000 (37-year old)
- Anonymous 37 Year Old Male v. Anonymous Emergency Physician; 2004 Jury Verdicts Award: \$800,000 (37-year old)
- CASE INFORMATION WITHHELD; 2009 MA Jury Verdicts Review Award: \$810,000 (14-year old)
- Campbell v. Allegheny University Hospital-Hahnemann Division; 2002 Jury Verdicts Award: \$8.5M (24-year old)

Source: LexisNexis

Summary

- Testicular salvage has been reported with NTT
- Asynchronous neonatal testicular torsion does occur
- The risks of taking a neonate to the operating room are decreasing with increasing use of awake-regional anesthesia
- The average length of time of a malpractice claim in this area is 5-years
- Substantial plaintiff verdicts have been awarded for lost testes

Quotes to Live By

“Errors of commission are always better than errors of omission.”

-Bartley Cilento, MD

“Plantiffs’ attorneys love it when doctors do nothing.”

-Grant Cannon, esq.